



## Whole exome sequencing in fetuses with isolated increased nuchal translucency: a systematic review and meta-analysis

Raffaella Di Girolamo, Giuseppe Rizzo, Asma Khalil, Sara Alameddine, Gabriele Lisi, Marco Liberati, Antonio Novelli & Francesco D'Antonio

To cite this article: Raffaella Di Girolamo, Giuseppe Rizzo, Asma Khalil, Sara Alameddine, Gabriele Lisi, Marco Liberati, Antonio Novelli & Francesco D'Antonio (2023) Whole exome sequencing in fetuses with isolated increased nuchal translucency: a systematic review and meta-analysis, The Journal of Maternal-Fetal & Neonatal Medicine, 36:1, 2193285, DOI: [10.1080/14767058.2023.2193285](https://doi.org/10.1080/14767058.2023.2193285)

To link to this article: <https://doi.org/10.1080/14767058.2023.2193285>



© 2023 The Author(s). Published by Informa UK Limited, trading as Taylor & Francis Group



[View supplementary material](#)



Published online: 05 Apr 2023.



[Submit your article to this journal](#)



Article views: 4223



[View related articles](#)



[View Crossmark data](#)



Citing articles: 5 [View citing articles](#)

## Whole exome sequencing in fetuses with isolated increased nuchal translucency: a systematic review and meta-analysis

Raffaella Di Girolamo<sup>a</sup>, Giuseppe Rizzo<sup>b</sup>, Asma Khalil<sup>c</sup>, Sara Alameddine<sup>a</sup>, Gabriele Lisi<sup>d</sup>, Marco Liberati<sup>a</sup>, Antonio Novelli<sup>e</sup> and Francesco D'Antonio<sup>a</sup>

<sup>a</sup>Centre for High-Risk Pregnancy and Fetal Care, Department of Obstetrics and Gynaecology, University of Chieti, Chieti, Italy;

<sup>b</sup>Department of Obstetrics and Gynaecology Fondazione Policlinico Tor Vergata, Università Roma Tor Vergata; <sup>c</sup>Fetal Medicine Unit, Saint George's Hospital, London, United Kingdom; <sup>d</sup>Pediatric Surgery Unit, Department of Medicine and Aging Science, University Gabriele D'Annunzio of Chieti-Pescara, Chieti, Italy; <sup>e</sup>Translational Cyto-genomics Research Unit, Bambino Gesù Children's Hospital, IRCCS, Rome, Italy

### ABSTRACT

**Objective:** To estimate the incremental yield of detecting pathogenic or likely pathogenic diagnostic genetic variants (DGV) by whole exome sequencing (WES) over standard karyotype and chromosomal microarray (CMA) analyses in fetuses with isolated increased nuchal translucency (NT) and normal fetal anatomy at the time of 11-14 weeks scan.

**Materials and Methods:** Medline and Embase databases were searched. Inclusion criteria were fetuses with NT >95<sup>th</sup> percentile, normal karyotype and CMA and no associated structural anomalies at the time of the 11-14 weeks scan. The primary outcome was to estimate the incremental yield of detecting pathogenic or likely pathogenic genetic variants by WES over standard karyotype and CMA analyses in fetuses with isolated increased nuchal translucency. The secondary outcomes were the detection of a genetic variant of unknown significance. Sub-analysis according to different NT cutoffs (between 3.0 and 5.5 mm and > 5.5 mm) and considering fetuses with isolated NT in which fetal anatomy was confirmed to be normal at the anomaly scan were also performed. Random effects model meta-analyses of proportion were used to analyze the data.

**Results:** Eight articles (324 fetuses) were included in the systematic review. Of the fetuses with negative standard karyotype and CMA analysis, the 8.07% (95% CI 5.4–11.3) had pathogenic or likely pathogenic genetic variants detected exclusively by WES. When stratifying the analysis according to NT cutoffs, genetic anomalies detected exclusively at WES analysis were found in 44.70% (95% CI 26.8–63.4) of fetuses with NT between 3.0 mm and 5.5 mm and 55.3% (95% CI 36.6–73.2) in those fetuses with NT >5.5 mm and positive WES results. The 7.84% (95% CI 1.6–18.2) had variants of unknown significance identified by WES. When considering fetuses with isolated increased NT and normal fetal anatomy at the anomaly scan, the rate of pathogenic or likely pathogenic genetic variants detected by WES was 3.87% (95% CI 1.6–7.1), while variants of unknown significance were detected in 4.27% (95% CI 2.2–7.0) of cases.

**Conclusions:** Pathogenic and likely pathogenic genetic variants detected by WES are present in a significant proportion of fetuses with increased NT but normal standard karyotype and CMA analysis, also when no anomalies are detected at the anomaly scan. Further large studies sharing objective protocols of imaging assessment are needed to confirm these findings and to elucidate which gene panels should be assessed in fetuses with isolated increased NT to rule out associated genetic anomalies, which may potentially impact post-natal outcomes.

### ARTICLE HISTORY

Received 30 April 2022  
Revised 13 March 2023  
Accepted 15 March 2023



### KEYWORDS

Nuchal translucency; WSE  
Prenatal diagnosis; normal karyotype; systematic review

## Introduction

Assessment of nuchal translucency (NT) at the time of 11–14 weeks scan represents an important part of first-trimester screening for chromosomal anomalies. Increased NT, defined as >95<sup>th</sup> percentile, is associated with a large variety of chromosomal and structural

anomalies, mainly cardiac [1]. On this basis, pregnancy presenting with increased fetal NT should be counseled about the possibility of undergoing invasive prenatal diagnosis. Of note, a significant proportion of fetuses with increased NT have clinically significant microdeletions or duplications detected only at chromosomal

**CONTACT** Francesco D'Antonio  [francesco.dantonio@unich.it](mailto:francesco.dantonio@unich.it)  Centre for High-Risk Pregnancy and Fetal Care, Department of Obstetrics and Gynecology, University of Chieti, Via dei Vestini 31, Chieti, 66100, Italy.

 Supplemental data for this article is available online at <https://doi.org/10.1080/14767058.2023.2193285>.

© 2023 The Author(s). Published by Informa UK Limited, trading as Taylor & Francis Group

This is an Open Access article distributed under the terms of the Creative Commons Attribution License (<http://creativecommons.org/licenses/by/4.0/>), which permits unrestricted use, distribution, and reproduction in any medium, provided the original work is properly cited. The terms on which this article has been published allow the posting of the Accepted Manuscript in a repository by the author(s) or with their consent.

microarray analysis (CMA), making this mandatory when assessing the genetic risk of these fetuses [2].

More recently, next-generation sequencing, including whole exome sequencing (WES), a genomic technique for sequencing the protein-coding regions of genes in a genome, has improved the identification of genetic disorders in fetuses with structural abnormalities.

Despite that, it has still to be fully elucidated whether fetuses with increased NT and no additional structural anomalies at the time of the 11-14 weeks scan should also undergo WES analysis, apart from the standard karyotype and CMA assessment. Most of the published studies and systematic reviews combined cases affected by other anomalies as well as, making extrapolation of objective evidence difficult [3,4].

The aim of this systematic review was to estimate the incremental yield of detecting pathogenic or likely pathogenic genetic variants by WES over standard karyotype and CMA analyses in fetuses with isolated increased NT.

## Materials and methods

This review was performed according to a protocol designed *a priori* and recommended for systematic review [5]. Medline and Embase databases were searched electronically on 25<sup>th</sup> April 2022, utilizing combinations of the relevant medical subject heading (MeSH) terms, key words, and word variants for “Nuchal translucency” “WES” and “genetic variants”. Reference lists of relevant articles and reviews were hand searched for additional reports. PRISMA guidelines were followed [6].

Inclusion criteria were fetuses with isolated increased NT, defined as above >95th percentile, normal fetal karyotype and CMA and normal fetal anatomy at the 11–14 weeks’ scan.

The primary outcome was to estimate the incremental yield of detecting pathogenic or likely pathogenic genetic variants by WES over standard karyotype and CMA analyses in fetuses with isolated increased nuchal translucency.

The secondary outcomes were:

- Genetic variant of unknown significance
- Pathogenic or likely pathogenic genetic variants according to different NT cutoffs (between 3.0 and 5.5 mm and > 5.5 mm respectively).

Furthermore, we aimed to ascertain the explored outcomes in fetuses with isolated NT in which fetal

anatomy was confirmed to be normal later on at the anomaly scan.

Pathogenic, likely pathogenic genetic variants and those of unknown significance were defined according to the joint consensus recommendation of the American College of Medical Genetics and Genomics and the Association for Molecular Pathology [7].

Only studies including fetuses with increased fetal nuchal translucency, normal standard karyotype and CMA analysis undergoing WES were considered suitable for inclusion [1,3,8–15]. Studies including fetuses with other anomalies, those without recorded NT measurement and those assessing only WES analysis in specific sub-group of conditions, such as hydrops, fetal growth restriction or pregnancies at higher risk of genetic anomalies due to family history were excluded [16–18]. Two authors (RDG, SA) reviewed all abstracts independently. Agreement regarding potential relevance was reached by consensus with a third reviewer (GR). Full-text copies of those articles were obtained, and the same two reviewers independently extracted relevant data. Inconsistencies were discussed and the consensus was reached, or the dispute was resolved by discussion with senior authors (FDA).

Only full-text articles were considered eligible for inclusion. Conference abstracts and single case reports were excluded to avoid publication bias. Quality assessment of the included studies was performed using the Newcastle-Ottawa Scale (NOS) for cohort studies [19]. According to NOS, each study is judged on three broad perspectives: the selection of the study groups; the comparability of the groups; and the ascertainment of the outcome of interest. Assessment of the selection of a study includes the evaluation of the representativeness of the exposed cohort, selection of the non-exposed cohort, ascertainment of exposure and the demonstration that the outcome of interest was not present at the start of the study. Assessment of the comparability of the study includes the evaluation of the comparability of cohorts based on the design or analysis. Finally, the ascertainment of the outcome of interest includes the evaluation of the type of assessment of the outcome of interest, length and adequacy of follow-up. According to NOS, a study can be awarded a maximum of one star for each numbered item within the selection and outcome categories. A maximum of two stars can be given for comparability [20].

We used random effects model of proportions to analyze the data. Tests for funnel plot asymmetry were not used when the total number of publications included for each outcome was less than ten. In this

case, the power of the tests is too low to distinguish chance from real asymmetry. Statistical heterogeneity among studies was assessed by the inconsistency index  $I^2$ . Heterogeneity was categorized as: null for  $I^2 = 0\%$ , minimal for  $I^2 < 25\%$ , low for  $25 < I^2 < 50\%$ , moderate for  $50 < I^2 < 75\%$  and high for  $I^2 \geq 75\%$ .

All analyses were performed using StatsDirect (StatsDirect Ltd. 2013) and Comprehensive Meta-Analysis (Biostat, Englewood, NJ 2013) statistical software.

## Results

The literature search yielded 383 results; 22 articles were identified, 13 were assessed with respect to their eligibility for inclusion and 8 studies were included in the systematic review (Table 1, Figure 1, Supplementary Table 1). The other studies were excluded based on the inclusion of only fetuses with anomalies or lack of information on NT results. The included studies included 324 fetuses with negative CMA and karyotype undergoing WES analysis. The studies by Lord et al. and Petrovsky et al. [10,11] were excluded from the pooled analysis of the primary outcome because they included cases already reported in the studies by Mellis et al. In detail, it includes all the Lord and Petrovski cases plus additional previously unreported cases, thereby increasing the sample [8].

The results of the quality assessment of the included studies using the Newcastle-Ottawa Scale (NOS) are presented in Table 2. The included studies showed an overall good score regarding the selection and comparability of the study groups, and for ascertainment of the outcome of interest.

Of the fetuses with negative standard karyotype and/or CMA analysis, 8.07% (95% CI 5.4–11.3) had pathogenic or likely pathogenic genetic variants detected exclusively by WES (Figure 2).

When stratifying the analysis according to NT cut-offs, genetic anomalies detected exclusively at WES analysis were found in the 44.70% (95% CI 26.8–63.4) of fetuses with NT between 3.0 mm and 5.5 mm and 55.30% (95% CI 36.6–73.2) in those with NT >5.5 mm and positive WES results. The 7.84% (95% CI 1.6–18.2) of fetuses had variants of unknown significance identified by WES (Table 3, Figure 2).

When considering fetuses with isolated increased NT and normal fetal anatomy at the anomaly scan, the rate of pathogenic or likely pathogenic genetic variants detected by WES was 3.87% (95% CI 1.6–7.1), while variants of unknown significance were detected in 4.27% (95% CI 2.2–7.0) of cases (Table 3).

## Discussion

The findings from this systematic review show that about 8% of fetuses with increased NT, normal standard karyotype and CMA analysis and normal fetal anatomy at the time of the 11–14 weeks' scan showed pathogenic or likely pathogenic genetic variants by WES, while variants of unknown significance were detected in about 8% of cases.

Thorough literature search, the inclusion of fetuses with isolated NT, and stratification of the analysis according to different NT cutoffs were the main strengths of the present systematic review. A small number of cases and a few included studies, their retrospective non-randomized design and heterogeneity in outcome assessment and definition represent

**Table 1.** General characteristics of the included studies in the present systematic review.

Authors	Country	Study design	Period considered	Definition of increased NT	Previous Genetic testing	Isolated increased NT (n)	Sequencing Approach
Mellis et al. 2021 [8]	United States	Retrospective	2014–2018	>3.5 mm	CMA	159	Trio WES
Xue et al. 2020 [9]	China	Prospective	2014–2017	>3.5 mm	CMA	274	Trio WES
Yang et al. 2020 [13]	China	Prospective	2017–2018	>3.5 mm	CMA	73	Trio CES
Chen et al. 2020 [14]	China	Prospective	NS	>3.5 mm	CMA	18	Trio CES
Daum et al. 2019 [3]	Israel	Retrospective	2012–2017	>3.5 mm	CMA	12	Solo and trio WES
Choy et al. 2019 [12]	China	Retrospective	2014–2018	>3.5 mm	CMA	34	GS
Leung et al. 2018 [15]	China	Retrospective	NS	>3.5 mm or cystic hygroma	CMA	4	Trio WES
Drury et al. 2015 [1]	United Kingdom	Prospective	NS	>3.5 mm	CMA	5	WES, trio and solo

NT: nuchal translucency; WES: whole exome sequencing; CMA: chromosomal microarray; GS: genome sequencing; CES: Capillary electrophoresis sequencing; NS: not specified.

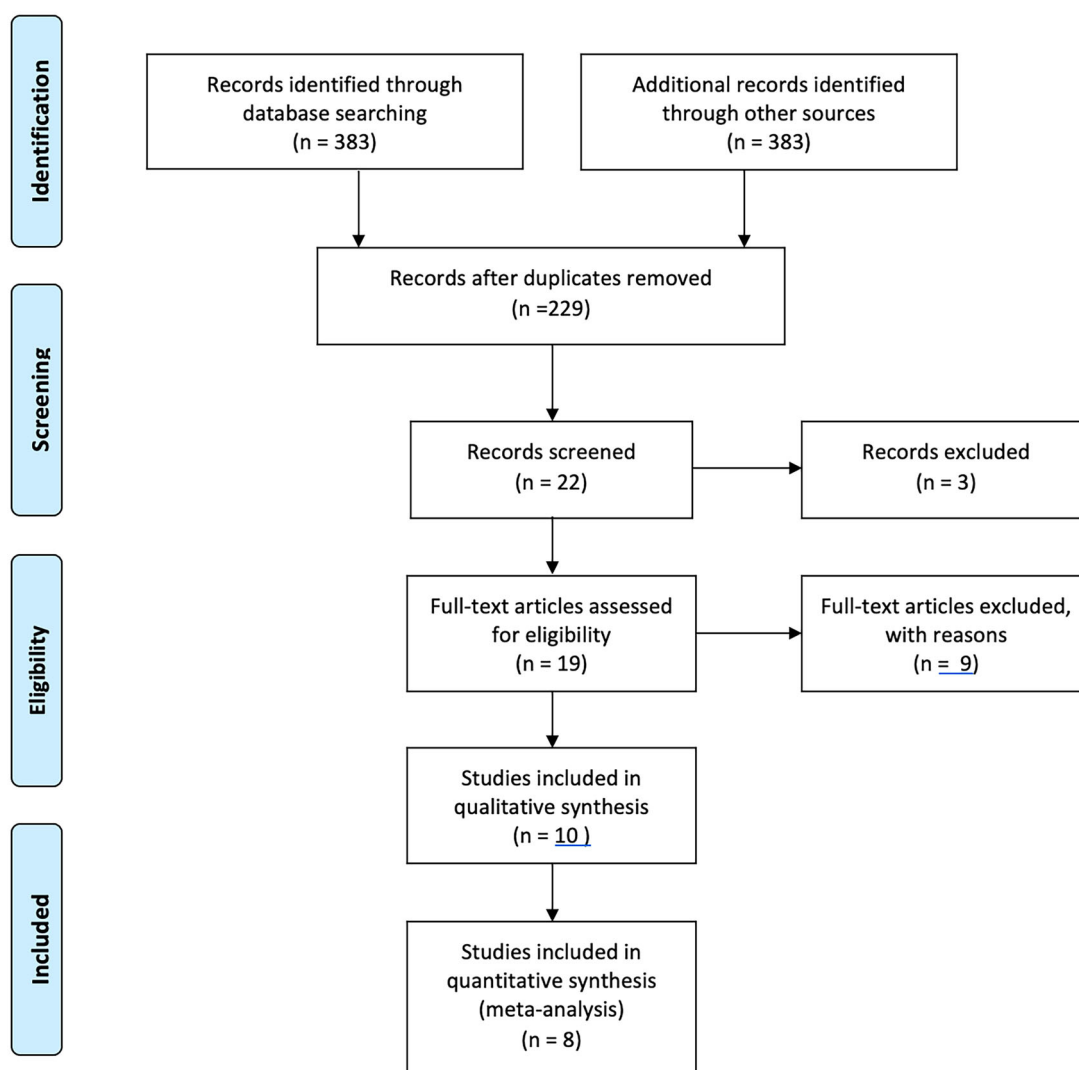


Figure 1. Prisma flow diagram.

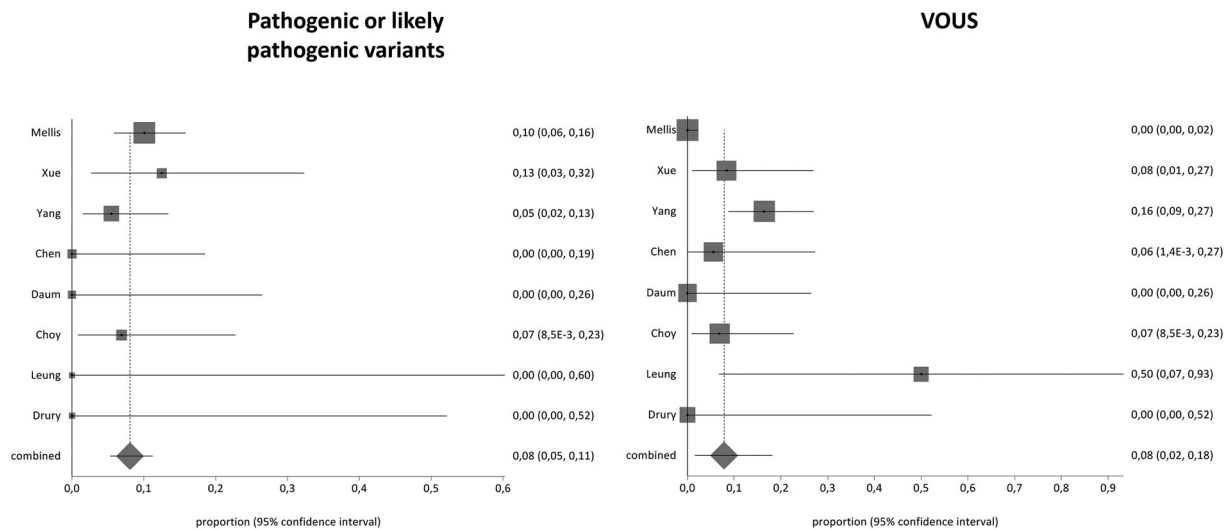
Table 2. Quality assessment of the included studies according to Newcastle-Ottawa Scale (NOS)\*.

Authors	Year	Selection	Comparability	Outcome
Mellis et al. 2021 [8]	United States	★★★	★★	★★
Xue et al. 2020 [9]	China	★★	★★	★★
Yang et al. 2020 [13]	China	★★	★★	★★
Chen et al. 2020 [14]	China	★★	★★	★★
Daum et al. 2019 [3]	Israel	★★	★	★
Choy et al. 2019 [12]	China	★★	★★	★
Leung et al. 2018 [15]	China	★★	★	★
Drury et al. 2015 [1]	United Kingdom	★	★	★

\*a study can be awarded a maximum of one star for each numbered item within the Selection and Outcome categories. A maximum of two stars can be given for Comparability.

the main limitations of our systematic review. Assessment of the potential publication bias was also problematic because of the nature of the outcome evaluated (outcome rates, with the left-side limited to a value of zero), which limits the reliability of funnel plots, and because of the scarce number of individual studies, which strongly limits the reliability of formal tests. Furthermore, we could not stratify the analysis

considering other factors potentially impacting the risk of genetic diseases, such as maternal age, a prior fetus with a genetic anomaly or structural malformations in view of the very small number of included cases and an even smaller number of events. Finally, we included only cases with normal fetal anatomy at the 11–14 weeks' scan, the imaging protocol adopted to rule out fetal anomalies in the first trimester was not



**Figure 2.** Pooled proportion for the occurrence of pathogenic or likely pathogenic variants in fetuses with isolated increased NT detected exclusively at WES analysis.

**Table 3.** Pooled proportions (95% CI) for the rate of pathogenetic or likely pathogenic genetic variants and for variants of unknown significance anomalies detected by WES in fetuses with increased NT and normal CMA and karyotype.

Outcome	Studies	Number of fetuses	Pooled proportions 95 CI (%)	$I^2$ (%) (95% CI)
<i>Cases with isolated increased NT</i>				
Pathogenic or likely pathogenic diagnostic variants	8	25/324	8.07 (5.4–11.3)	0 (0–56.3)
NT between 3.0 and 5.5	4	11/25	44.70 (26.8–63.4)	0 (0–67.9)
NT >5.5	4	14/25	55.30 (36.6–73.2)	0 (0–67.9)
Variants of unknown significance	8	19/324	7.84 (1.6–18.2)	82.6 (64–89.5)
<i>Cases with isolated increased NT and no structural anomalies at the anomaly scan</i>				
Pathogenic or likely pathogenic diagnostic variants	8	9/276	3.87 (1.6–7.1)	18.5 (0–63.9)
Variants of unknown significance	8	10/276	4.27 (2.2–7.0)	0 (0–56.3)

NT: nuchal translucency; CMA: chromosomal microarray.

consistently reported in detail by the different studies and it may be entirely possible that inclusion of cases affected by structural anomalies not detected at first-trimester scan might have biased the results.

A recent systematic review [17] assessing the rate of pathogenic genetic variants detected exclusively by WES in fetuses with increased NT, reported that a pathogenic or likely pathogenic variant was found in 4% of cases (95% CI: 2% to 6%). The observed inheritance pattern was autosomal dominant in 12 cases. Despite the similarity in the study design with the present review, the study by Pauta et al. included also cases affected by structural fetal anomalies and specific sub-set of fetuses, such as those with hydrops, which represents a potential source of bias in view of the increased risk of genetic anomalies in fetuses with structural malformations. Conversely, the present systematic review included only fetuses with no associated anomaly. Furthermore, we reported the risk of detecting pathogenic or likely pathogenic genetic variants by WES according to NT cutoff and the presence of normal anatomy at the second-trimester anomaly scan.

NT assessment at the 11–14 weeks scan allows for a primary risk stratification for fetal aneuploidy and structural anomalies. Pregnant women with increased fetal NT are routinely offered invasive prenatal diagnosis and early assessment of fetal anatomy to allow early detection of genetic anomalies or structural malformations [21–24]. Recent studies and systematic reviews reported that in case of increased NT, CMA analysis should be offered apart from the standard karyotype as it may detect additional clinically relevant genetic anomalies not identified at the standard karyotype analysis.

More recently, next-generation sequencing, including whole exome sequencing (WES), a genomic technique for sequencing all the protein-coding regions of genes in a genome, has merged as a new technique able to identify genetic disorders in fetuses with structural abnormalities, not detected by standard karyotype and CMA analysis. Several studies have reported the additional contribution of WES in identifying single gene disorders in fetuses with a prenatal diagnosis of structural malformations or in pregnancies at high risk of genetic disorders such as those with a positive

family history of disability [25]. Despite that, clinical integration of WES in prenatal diagnosis is still in very preliminary stages. An increased NT may be also related to monogenic syndromes, especially when no structural anomalies are detected at the scan. The findings from this systematic review confirmed the diagnostic role of WES in identifying fetuses with pathogenic or likely pathogenic genetic variants even in fetuses not showing structural malformations later at the anomaly scan [26]. The presence of VOUS in a fetus with increased NT represents another peculiar issue. Because no complete phenotype is present until birth, identification of VOUS prenatally may pose a peculiar challenge during prenatal counseling. Detection of a structural anomaly later at the anomaly scan in fetuses with increased NT and VOUS identified at WES may increase the risk of adverse outcomes and this should be reported to parents. Conversely, in fetuses with increased NT and no anomalies at the scan, the presence of a VOUS may represent a relatively benign condition.

The whole exome comprises approximately 1 to 2% of the genome, and exome sequencing (ES) enables the assessment of the coding regions of more than 20,000 genes. However, to simplify interpretation and minimize inconclusive findings, instead of whole WES, ES can be restricted to the analysis of the coding sequences of the OMIM genes (clinical or medical ES) or focused only on specific genes associated with the observed fetal phenotype (gene panels) [27,28].

## Conclusion

Pathogenic and likely pathogenic genetic variants detected by WES are present in a significant proportion of fetuses with increased NT but normal standard karyotype and CMA analysis, also when no anomalies are detected at the anomaly scan. Further large studies sharing objective protocols of imaging assessment are needed to confirm these findings and to elucidate which gene panels should be assessed in fetuses with isolated increased NT to rule out associated genetic anomalies, which may potentially impact post-natal outcomes.

## Disclosure statement

No potential conflict of interest was reported by the author(s).

## Funding

The author(s) reported there is no funding associated with the work featured in this article.

## References

- [1] Drury S, Williams H, Trump N, GOSGene, et al. Exome sequencing for prenatal diagnosis of fetuses with sonographic abnormalities. *Prenat Diagn.* 2015; 35(10):1010–1017.
- [2] Wilson KL, Czerwinski JL, Hoskovec JM, et al. NSGC practice guideline: prenatal screening and diagnostic testing options for chromosome aneuploidy. *J Genet Couns.* 2013;22(1):4–15.
- [3] Daum H, Meiner V, Elpeleg O, collaborating authors, et al. Fetal exome sequencing: yield and limitations in a tertiary referral center. *Ultrasound Obstet Gynecol.* 2019; 53(1):80–86.
- [4] Carss KJ, Hillman SC, Parthiban V, et al. Exome sequencing improves genetic diagnosis of structural fetal abnormalities revealed by ultrasound. *Hum Mol Genet.* 2014;23(12):3269–3277.
- [5] Higgins JPT, Green S. *Cochrane Handbook for Systematic Reviews of Interventions* [Internet]. The Cochrane Collaboration; 2011. Available from: [www.cochrane-handbook.org](http://www.cochrane-handbook.org).
- [6] Moher D, Liberati A, Tetzlaff J, PRISMA Group, et al. Preferred reporting items for systematic reviews and meta-analyses: the PRISMA statement. *PLoS Med.* 2009; 16(7):e1000097.
- [7] Richards S, Aziz N, Bale S, et al. Standards and guidelines for the interpretation of sequence variants: a joint consensus recommendation of the American college of medical genetics and genomics and the association for molecular pathology. *Genet Med.* 2015; 17(5):405–424.
- [8] Mellis R, Eberhardt RY, Hamilton SJ, PAGE Consortium, et al. Fetal exome sequencing for isolated increased nuchal translucency: should we be doing it? *BJOG.* 2022;129(1):52–61.
- [9] Xue S, Yan H, Chen J, et al. Genetic examination for fetuses with increased fetal nuchal translucency by genomic technology. *Cytogenet Genome Res.* 2020; 160(2):57–62.
- [10] Lord J, McMullan DJ, Eberhardt RY, et al. Prenatal exome sequencing analysis in fetal structural anomalies detected by ultrasonography (PAGE): a cohort study. *Lancet.* 2019; 393(10173):747–757.
- [11] Petrovski S, Aggarwal V, Giordano JL, et al. Whole-exome sequencing in the evaluation of fetal structural anomalies: a prospective cohort study. *Lancet.* 2019; 393(10173):758–767.
- [12] Choy KW, Wang H, Shi M, et al. Prenatal diagnosis of fetuses with increased nuchal translucency by genome sequencing analysis. *Front Genet.* 2019; 10:761.
- [13] Yang X, Huang LY, Pan M, et al. Exome sequencing improves genetic diagnosis of fetal increased nuchal translucency. *Prenat Diagn.* 2020;40(11):1426–1431.
- [14] Chen M, Chen J, Wang C, et al. Clinical application of medical exome sequencing for prenatal diagnosis of fetal structural anomalies. *Eur J Obstet Gynecol Reprod Biol.* 2020;251:119–124.
- [15] Leung GKC, Mak CCY, Fung JLF, et al. Identifying the genetic causes for prenatally diagnosed structural congenital anomalies (SCAs) by whole-exome sequencing (WES). *BMC Med Genomics.* 2018; 11(1):93.

- [16] Sparks TN, Lianoglou BR, Adami RR, et al. University of California fetal–maternal consortium; university of California, san francisco center for maternal–fetal precision medicine. Exome sequencing for prenatal diagnosis in nonimmune hydrops fetalis. *N Engl J Med*. 2020;383(18):1746–1756.
- [17] Pauta M, Campos B, Segura-Puimedon M, et al. A. Next-Generation sequencing gene panels and “solo” clinical exome sequencing applied in structurally abnormal fetuses. *Fetal Diagn Ther*. 2021;48(10):746–756.
- [18] Pauta M, Martinez-Portilla R, Borrell A. Diagnostic yield of exome sequencing in fetuses with an isolated increased nuchal translucency: systematic review and meta-analysis. *Ultrasound Obstet Gynecol*. 2022;59(1):26–32.
- [19] Lo CK, Mertz D, Loeb M. Newcastle-Ottawa scale: comparing reviewers’ to authors’ assessments. *BMC Med Res Methodol*. 2014;14:45.
- [20] Whiting P, Rutjes AW, Reitsma JB, et al. The development of QUADAS: a tool for the quality assessment of studies of diagnostic accuracy included in systematic reviews. *BMC Med Res Methodol*. 2003;3:25.
- [21] Carbone L, Cariati F, Sarno L, et al. Non-Invasive prenatal testing: current perspectives and future challenges. *Genes (Basel)*. 2020;12(1):15.
- [22] Syngelaki A, Hammami A, Bower S, et al. Diagnosis of fetal non-chromosomal abnormalities on routine ultrasound examination at 11-13 weeks’ gestation. *Ultrasound Obstet Gynecol*. 2019;54(4):468–476.
- [23] D’Amico A, Buca D, Rizzo G, et al. Outcome of fetal echogenic bowel: a systematic review and meta-analysis. *Prenat Diagn*. 2021;41(4):391–399.
- [24] Di Mascio D, Buca D, Khalil A, et al. Outcome of isolated fetal talipes: a systematic review and meta-analysis. *Acta Obstet Gynecol Scand*. 2019;98(11):1367–1377.
- [25] Committee on Genetics and the Society for Maternal-Fetal Medicine. Committee opinion no.682: microarrays and Next-Generation sequencing technology: the use of advanced genetic diagnostic tools in obstetrics and gynecology. *Obstet Gynecol*. 2016;128:e262. Reaffirmed 2019.
- [26] Rabbani B, Tekin M, Mahdih N. The promise of whole-exome sequencing in medical genetics. *J Hum Genet*. 2014;59(1):5–15.
- [27] Hu T, Tian T, Zhang Z, et al. Prenatal chromosomal microarray analysis in 2466 fetuses with ultrasonographic soft markers: a prospective cohort study. *Am J Obstet Gynecol*. 2021;224(5):516.e1–516.e16.
- [28] Shaffer LG, Rosenfeld JA, Dabell MP, et al. Detection rates of clinically significant genomic alterations by microarray analysis for specific anomalies detected by ultrasound. *Prenat Diagn*. 2012;32(10):986–995.