

Extra anatomical cryopreserved homograft solution for recurrent femoropopliteal bypass infection

Alberto M Settembrini^{a,b,#,*}, Leonardo Foresti^{a,#}, Giuseppe Cannizzo^a, Silvia Romagnoli^a, Daniele Bissacco^b, Santi Trimarchi^{a,b}

^a Department of Cardio Thoracic and Vascular Diseases, Fondazione IRCCS Ca' Granda Ospedale 7 Maggiore Policlinico, Milan, Italy

^b Department of Clinical and Community Sciences, University of Milan, Università degli Studi di Milano, Milan, Italy

ARTICLE INFO

Keywords:

Vascular graft infection
Peripheral bypass
Extra-anatomic bypass
Homograft
Vascular graft excision

ABSTRACT

Introduction Vascular graft infections (VGIs) are challenging and potentially life-threatening complications following femoropopliteal bypasses. The treatments of choice in peripheral VGIs are antimicrobial therapy, surgical excision, and in-situ reconstruction with an autologous superficial vein. An extraanatomical homograft bypass and antimicrobial therapy could be resolute in patients presenting with recurrent VGIs and unavailable autologous veins.

Case Report We present the case of a 74-year-old Caucasian man with a history of a below-the-knee (BTK) right femoropopliteal bypass using polytetrafluoroethylene (PTFE) for chronic peripheral artery disease (Rutherford Grade 3). He presented at the emergency department with septic arthritis of the right knee involving the previous PTFE femoropopliteal bypass. The graft was excised, and an in-situ saphenous vein BTK femoropopliteal bypass was performed. Due to multiple recurrences of graft infection of the proximal anastomosis, an extra-anatomical cryopreserved arterial homograft reconstruction from the external iliac artery to the profunda femoral artery was necessary as a definitive treatment. At three years follow-up the patient is alive, with patency of both vascular reconstructions.

Conclusion Despite aggressive treatment, managing vascular graft infections can be challenging, typically requiring a blend of surgical and medical interventions. Patient-specific surgical approaches, such as graft removal, infected tissue debridement and extra-anatomical reconstruction with biological grafts is crucial. In those patients with unavailable autologous veins, consideration could be given to a cryopreserved homograft due to its resistance against infections.

1. Introduction

Peripheral vascular graft infections (VGIs) following femoropopliteal prosthetic bypasses^{1,2} is relatively rare postoperative complication, with a reported incidence ranging from 2.5 % to 2.8 % but a significant limb loss and mortality risk.³ Current treatment of choice involves antimicrobial therapy and radical surgical excision followed by in-situ reconstruction with autologous great saphenous vein (GSV) or other

biological grafts.⁴ Due to the high rate of amputation, reinfection, and mortality risk (up to 45 % at five years), non-surgical options should be considered only in patients deemed unfit for surgery.⁵

We report a case of an infected below-the-knee (BTK) femoropopliteal polytetrafluoroethylene (PTFE) bypass, treated with an iliac-femoral extra-anatomical homograft bypass combined to in-situ femoropopliteal BTK bypass and antimicrobial therapy in presence of recurrent peripheral VGIs.

Abbreviations: BTK, Below-the-knee; BPP, Bovine pericardium patch; CFA, Common femoral artery; DUS, Duplex ultrasound; MRSA, Methicillin-Resistant Staphylococcus Aureus; PFA, Profunda femoral artery; PTFE, Polytetrafluoroethylene; SAPT, Single antiplatelet therapy; VGI, vascular graft infections.

Disclosures: None.

* Corresponding author at: Vascular Surgery Department, Fondazione IRCCS Ca' Granda Ospedale Maggiore, Policlinico, Via Francesco Sforza 35, 20122 Milan, Italy.

E-mail addresses: alberto.settembrini@unimi.it (A.M. Settembrini), leonardo.foresti@unimi.it (L. Foresti), giuseppe.cannizzo@unimi.it (G. Cannizzo), silvia.romagnoli@policlinico.mi.it (S. Romagnoli), santi.trimarchi@unimi.it (S. Trimarchi).

These authors shared the first authorship

<https://doi.org/10.1016/j.avsurg.2024.100292>

Received 4 March 2024; Received in revised form 13 May 2024; Accepted 16 May 2024

Available online 18 May 2024

2772-6878/© 2024 The Author(s). Published by Elsevier Inc. This is an open access article under the CC BY-NC-ND license (<http://creativecommons.org/licenses/by-nc-nd/4.0/>).

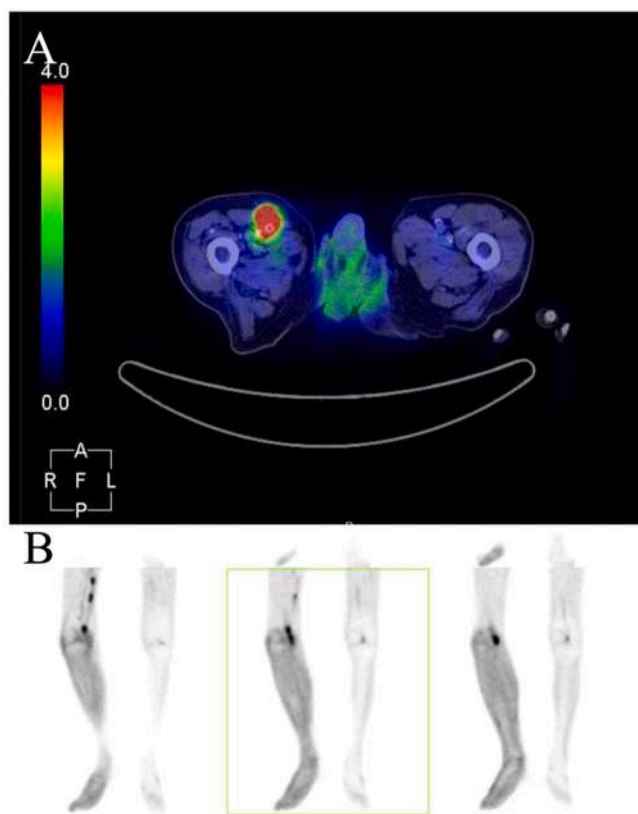


Fig. 1. PET-CT scan. The FDG uptake confirms infection extending from the proximal (A) to the distal part (B) of the previous femoropopliteal bypass.

This case report has been described in line with the PROCESS guidelines.⁶

2. Report

We present the case of a 74-year-old Caucasian male with a medical history of hypertension, dyslipidaemia, chronic obstructive pulmonary disease, coronary artery disease and stage 3 chronic kidney disease. In 2004, he underwent PTFE right BTK femoropopliteal bypass for chronic Rutherford Class 3 peripheral artery disease, due to an occlusion of the popliteal artery, at another centre. Since then, he started single antiplatelet therapy (SAPT). In November 2019, the patient underwent percutaneous drainage of a right pelvic lymphocele, performed by a urologist at another centre, which developed following bilateral pelvic lymphadenectomy performed during a radical prostatectomy for cancer. Despite the presence of fever and positive blood cultures, the patient was initiated on antibiotic therapy solely based on blood cultures, without conducting culture tests on the drained fluid. This decision was taken because of the multidisciplinary assessment of the postprostatectomy computed tomography (CT), which ruled out potential infectious involvement of the lymphocele.

In January 2020, the patient self-presented to our emergency department, for the first time, with knee pain, current fever, and weakness. At the nasopharyngeal swab he tested positive for SARS-CoV2. He was admitted with the diagnosis of right knee septic arthritis. Blood cultures were obtained, and he was transferred to the internal medicine department to start broad-spectrum antibiotic therapy. Subsequent blood cultures revealed Methicillin-Resistant *Staphylococcus Aureus* (MRSA), and targeted antibiotic therapy was immediately started. After nine days of treatment, blood cultures were repeated and turned negative. A CT angiography (CTA) ruled out knee and body district colonization, showing right knee joint effusion, with no sign of VGI.

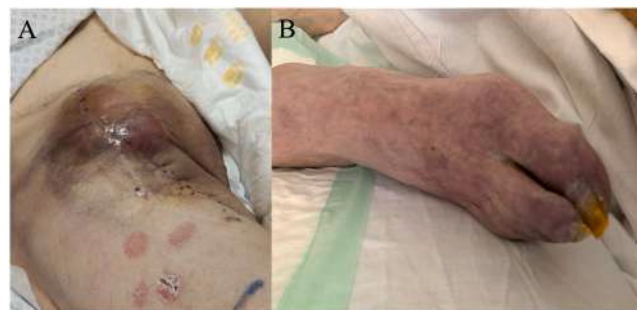

Fig. 2. Patient' clinical presentation with recurrent right groin hematoma (A) compressing the in-situ vein bypass and determining poikilothermic, painful, cyanotic, and pale right limb (B).

Arthrocentesis confirmed MRSA in joint fluid, guiding ongoing antibiotic treatment according to the antibiogram. Following seven days of antibiotic therapy, the patient underwent arthroscopic debridement and drainage of the right knee by an orthopaedic surgeon. Joint fluid samples collected during the surgery showed negative cultures in the subsequent days. Patient was discharged after 25 days, afebrile with reduced edema, but persistent knee pain and limited limb extension, without any other sign of recurrent infection. As recommended by the infectious disease specialist, he was discharged to a rehabilitation clinic to continue the long-term antibiotic therapy for up to 4 weeks after the debridement.

In April 2020, the patient reported a fever after the end of the antibiotic therapy period in the rehabilitation clinic. Blood cultures were performed and tested positive for MRSA, so targeted antibiotic therapy was restarted. On the same day, he tested positive for SARS-CoV2 and was readmitted to our emergency department with the diagnosis of persistent bacteraemia and SARS-CoV2 infection. At the admission, the right knee was slightly swollen, but no other signs of infection were present. In the suspect of an underlying recurrent infection of the knee, a PET-CT scan was performed and showed a VGI without any involvement of the knee (Fig. 1). In a surgical COVID setting,⁷ we proceeded to the radical excision of the infected graft, debridement of the surgical access sites, and reconstruction with an in-situ GSV BTK femoropopliteal bypass after common femoral artery (CFA) endarterectomy and bovine pericardium patch (BPP) angioplasty. On postoperative day 1, subcutaneous low-molecular-weight heparin 4000 UI twice daily was started. Cultures of the graft samples collected during the surgery resulted positive for *Proteus mirabilis*, so antibiotic therapy was continued based on the antibiogram. On postoperative day 7, the patient showed progressive anaemia associated with a slowly growing groin hematoma present since the surgery. CTA was performed, revealing no active bleeding but a compressing groin hematoma which was immediately surgically evacuated without any sign of graft or patch detachment. Anticoagulation therapy was switched to prophylactic anticoagulation with Fondaparinux 2,5 mg once daily, and the SAPT was suspended. Intraoperative samples were collected and tested positive for *Klebsiella pneumoniae* and *Candida albicans*; antibiotic therapy was then changed according to the antibiogram. On postoperative day 10, the patient presented a haemorrhagic shock caused by femoral patch detachment, probably due to a hidden recurrent VGI. In an emergency setting, after the resolution of the acute bleeding, since no biological or silver coated graft was available a PTFE bypass was performed extending proximally to the common femoral artery, just above the inguinal ligament, and distally to the femoral bifurcation with an end-to-end anastomosis. During the postoperative course, anticoagulation and SAPT were restarted. After 42 days of recovery, he was discharged to the rehabilitation clinic to end the long-term antibiotic therapy without any relevant limb complaints.

In July 2020, 10 days after the discharge, the patient was referred by the clinicians of the rehabilitation clinic to our emergency department for poikilothermic, painful, cyanotic, and pale right limb with recurrent

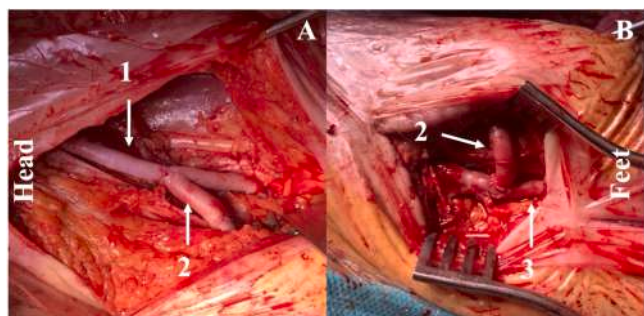


Fig. 3. Extra-anatomical cryopreserved homograft. Lateral (A) and medial (B) view of the extraanatomical homograft bypass between the external iliac artery and the profunda femoral artery (1) completed by a jump-bypass in homograft (2) from the profunda artery to the previous in-situ saphenous bypass (3).

groin hematoma (Fig. 2). Suspecting acute ischemia, a duplex ultrasound (DUS) was performed, revealing a large groin hematoma compressing the saphenous graft causing a low flow in the in-situ bypass, confirmed by a CTA which showed a CFA anastomotic pseudoaneurysm raising the suspect of a recurrent VGI. Therefore, in an urgent setting, we decided to perform a complete radical excision of the previous PTFE graft, extensive debridement, and arterial revascularization with an extra-anatomical homograft cryopreserved bypass (cadaver femoral artery) between the external iliac artery through the lateral course from the iliac crest, and the profunda femoral artery (PFA) laterally to sartorius muscle and a jump-bypass, with same homograft, from the PFA to the previous in-situ GSV bypass (Fig. 3A and B). Samples were collected from the previous PTFE graft and cultures resulted positive for *Candida albicans*, so a life-long targeted antifungal therapy was started. Postoperative DUS proved a complete restoration of the flow in the vein graft; so, the patient was discharged after 17 days with mild right limb paraesthesia but no claudication. The postoperative management was characterized by subcutaneous low-molecular-weight heparin 4000 UI once daily for four weeks combined with life-long SAPT.

Follow-up was performed with clinical and DUS examinations at our centre at 1, 3, and 6 months and annually. At three-year follow-up, no new infections occurred, and DUS showed regular patency of the bypasses (Fig. 4). Nowadays, the patient's clinical conditions allow him to be autonomous in everyday life.

3. Discussion

The possibility of saving the native graft depends not only on the extent of the infection but also on the type of microorganism involved⁸. Generally, excision of the graft is feasible if the anastomosis is preserved, according to the Samson classification, but it is not recommended if MRSA, *P. aeruginosa*, and multi-drug resistance microorganism are involved⁹. In this case our initial approach was in-situ reconstruction using autologous GSV after CFA BPP angioplasty.

While the choice of a GSV in-situ bypass is widely accepted and recommended,⁴ recent literature supports BPP over autologous vein patch¹¹. Nevertheless, a recurrence of VGI occurred, leading to patch detachment. A PTFE graft was used for limb salvage in an emergency with no alternative grafts. Recognizing infection recurrence risk, a homograft was procured for potential emergencies. Despite targeted antibiotic therapy, a new recurrence occurred, prompting treatment with an extraanatomical homograft, ultimately resolving the case.

When autologous veins are unavailable, opting for a homograft can be justified by recognized benefits, including infection resistance, reduced surgery duration, and comorbidity during deep vein harvesting, however, limited availability and costs constrain its utilization and silver-coated graft is considered an effective and less expensive alternative.¹⁰ Furthermore, extra-anatomical routing could be recommended when multidrug-resistant bacteria and a hostile zone due to recurrent surgery are present.⁴ Considering the complexity of surgery in high-risk population, this approach could be deemed safe and associated with acceptable long-term outcomes in terms of amputation-free survival rate and limb salvage, whether it involves lateral retrosartorius or obturator bypass. However, in contrast with our long-term follow-up, some concerns persist regarding long-term patency.¹² Despite some literature reports risk for graft thrombosis, reinterventions and complications of these grafts and technique,^{5,13-15} in our case, at the 3-year follow-up, patency is maintained, and the patient has not undergone any reintervention or experienced any complications. Thus, we suggest, supported by evidence of acceptable midterm results,⁵ considering using homograft with extra-anatomical routing as a viable option in treating complex VGI. However, considering the lack of data and consensus on long-term outcomes, a careful and strict follow-up for this patient population is necessary.

4. Conclusion

This case underscores the potential recurrence and resistance of VGI. An extra-anatomical route with an allograft could be viable for complex vascular reconstruction in infected and surgically hostile fields. Early diagnosis, strict follow-up, targeted antibiotic therapy and a patient-tailored surgical approach, are crucial for favourable outcomes.

CRedit authorship contribution statement

Alberto M Settembrini: Visualization, Writing – review & editing, Writing – original draft, Resources, Methodology, Investigation, Data curation, Conceptualization. **Leonardo Foresti:** Writing – review & editing, Writing – original draft, Resources, Data curation, Conceptualization, Validation, Investigation. **Giuseppe Cannizzo:** Writing – original draft, Resources, Investigation, Conceptualization. **Silvia Romagnoli:** Methodology, Writing – review & editing, Conceptualization. **Daniele Bissacco:** Writing – original draft, Visualization, Methodology, Conceptualization. **Santi Trimarchi:** Writing – review & editing.

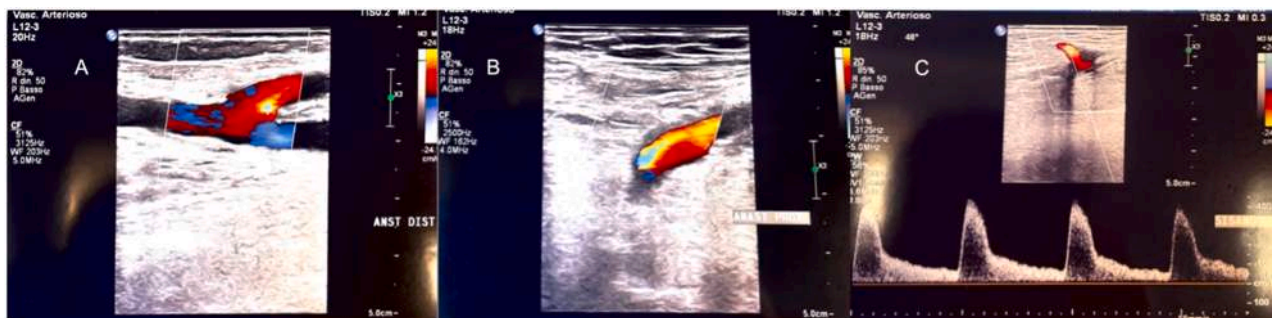

Fig. 4. Two years follow-up DUS exam. Patency of the extra-anatomical bypasses (A, B) and of the in-situ bypass (C).

Declaration of competing interest

The authors declare that they have no known competing financial interests or personal relationships that could have appeared to influence the work reported in this paper.

Acknowledgements

None.

Funding

This research did not receive any specific grant from funding agencies in the public, commercial, or not-for-profit sectors.

Patient consent statement

The patient consented to publishing the data and the images associated with this case report.

References

- Eiberg JP, Røder O, Stahl-Madsen M, Eldrup N, Qvarfordt P, Laursen A, et al. Fluoropolymer-coated Dacron Versus PTFE Grafts for Femorofemoral Crossover Bypass: randomised Trial. *Eur J Vasc Endovasc Surg.* 2006;32(4):431–438.
- Exton RJ, Galland RB. Major Groin Complications Following the Use of Synthetic Grafts. *Eur J Vasc Endovasc Surg.* 2007;34(2):188–190.
- Revest M, Camou F, Senneville E, Caillon J, Laurent F, Calvet B, et al. medical treatment of prosthetic vascular graft infections: review of the literature and proposals of a Working Group. *Int J Antimicrob Agents.* 2015;46(3):254–265.
- Chakfé N, Diener H, Lejay A, Assadian O, Berard X, Caillon J, et al. Editor's Choice – European Society for Vascular Surgery (ESVS) 2020 Clinical Practice Guidelines on the Management of Vascular Graft and Endograft Infections. *Eur J Vasc Endovasc Surg.* 2020;59(3):339–384.
- Lejay A, Delay C, Girsowicz E, Chenesseau B, Bonnin E, Ghariani MZ, et al. Cryopreserved Cadaveric Arterial Allograft for Arterial Reconstruction in Patients with Prosthetic Infection. *Eur J Vasc Endovasc Surg.* 2017;54(5):636–644.
- Agha RA, Borrelli MR, Farwana R, et al. The PROCESS 2018 Statement: updating Consensus Preferred Reporting of CasE Series in Surgery (PROCESS) Guidelines. *Int J Surg.* 2018;60:279–282.
- Settembrini AM, Bissacco D, Romagnoli S, Trimarchi S. Vascular Surgeon Discomfort in a Pandemic Setting. *Ann Vasc Surg.* 2020;69:89. <https://doi.org/10.1016/j.avsg.2020.07.016>. NovEpub 2020 Jul 28. PMID: 32736024; PMCID: PMC7386307.
- Wilson Walter R, Chair MD, Bower Thomas C, Mark MD, Creager A, Vascular GraftInfections MD. Mycotic Aneurysms, and Endovascular Infections: a Scientific Statement from the American Heart Association. *Circulation.* 2016;34(20):e412.
- Zetrenne E, McIntosh BC, McRae MH, Gusberg R, Evans GR, Narayan D. Prosthetic vascular graft infection: a multi-center review of surgical management. *Yale J Biol Med.* 2007 Sep;80(3):113–121. PMID: 18299723; PMCID: PMC2248286.
- Bisdas T, Wilhelmi M, Haverich A, Teebken OE. Cryopreserved arterial homografts vs silver-coated Dacron grafts for abdominal aortic infections with intraoperative evidence of microorganisms. *J Vasc Surg.* 2011 May;53(5):1274–1281. <https://doi.org/10.1016/j.jvs.2010.11.052>. e4Epub 2011 Feb 2. PMID: 21292430.
- Noronen K, Söderström M, Kouhia S, Venermo M. Bovine pericardial patch: a good alternative in femoral angioplasty. *J Vasc Surg.* 2023 Jan;77(1):225–230. <https://doi.org/10.1016/j.jvs.2022.08.010>. Epub 2022 Aug 18. PMID: 35987464.
- Wang SK, Gutwein AR, Drucker NA, Murphy MP, Fajardo A, Dalsing MC, et al. Cryopreserved Homografts in Infected Infragaingual Fields Are Associated with Frequent Reinterventions and Poor Amputation-Free Survival. *Ann Vasc Surg.* 2018; 49:24–29.
- Minga Lowampa E, Holemans C, Stiennon L, Van Damme H, Defraigne JO. Late Fate of Cryopreserved Arterial Allografts. *Eur J Vasc Endovasc Surg.* 2016 Nov;52(5): 696–702. <https://doi.org/10.1016/j.ejvs.2016.08.005>. Epub 2016 Sep 7. PMID: 27614553.
- Randon C, Jacobs B, De Ryck F, Beele H, Vermassen F. Fifteen years of infrapopliteal arterial reconstructions with cryopreserved venous allografts for limb salvage. *J Vasc Surg.* 2010 Apr;51(4):869–877. <https://doi.org/10.1016/j.jvs.2009.11.062>. PMID: 20347683.
- Wilson WR, Bower TC, Creager MA, Amin-Hanjani S, O'Gara PT, Lockhart PB, et al. Vascular Graft Infections, Mycotic Aneurysms, and Endovascular Infections: a Scientific Statement from the American Heart Association. *Circulation.* 2016;134 (20):e412–e460.