



# Clinical delineation of 18q11-q12 microdeletion: Intellectual disability, speech and behavioral disorders, and conotruncal heart defects

Kitiwan Rojnueangnit<sup>1</sup>  | Chariyawan Charalsawadi<sup>2</sup> | Weerin Thammachote<sup>3</sup> | Ariya Pradabmuksiri<sup>1,4</sup> | Thipwimol Tim-Aroon<sup>5</sup>  | Antonio Novelli<sup>6</sup> | Sara Loddo<sup>6</sup> | Silvana Briuglia<sup>7</sup> | Cutrupi M. Concetta<sup>8</sup> | Duangrurdee Wattanasirichaigoon<sup>5</sup> | Natini Jinawath<sup>3,9</sup>

<sup>1</sup>Department of Pediatrics, Faculty of Medicine, Thammasat University, Bangkok, Thailand

<sup>2</sup>Division of Human Genetics, Department of Pathology, Faculty of Medicine, Prince of Songkla University, Hat Yai, Thailand

<sup>3</sup>Program in Translational Medicine, Faculty of Medicine Ramathibodi Hospital, Mahidol University, Bangkok, Thailand

<sup>4</sup>Division of Pediatrics, Surat Thani Hospital, Surat thani, Thailand

<sup>5</sup>Division of Medical Genetics, Department of Pediatrics, Faculty of Medicine Ramathibodi Hospital, Mahidol University, Bangkok, Thailand

<sup>6</sup>Laboratory of Medical Genetics, Bambino Gesù Children's Hospital, IRCCS, Rome, Italy

<sup>7</sup>Department of Bio-Morphology, Genetics Unit, University of Messina, Messina, Italy

<sup>8</sup>Department of Pediatrics, University of Messina, Messina, Italy

<sup>9</sup>Integrative Computational Bioscience Center, Mahidol University, Nakhon Pathom, Thailand

## Correspondence

Duangrurdee Wattanasirichaigoon,  
Division of Medical Genetics, Department  
of Pediatrics, Faculty of Medicine  
Ramathibodi Hospital, Mahidol University,  
Bangkok 10400, Thailand.  
Email: duangrurdee.wat@mahidol.ac.th

Natini Jinawath, Program in Translational  
Medicine, Faculty of Medicine  
Ramathibodi Hospital, Mahidol University,  
Bangkok 10400, Thailand.  
Email: jnatini@hotmail.com

## Funding information

Mahidol University

## Abstract

**Background:** Since the establishment of chromosomal microarrays in clinical practice, many new microdeletion/microduplication syndromes have been identified, including 18q11.2 microdeletion. Chromosome 18q deletion syndrome is commonly classified into distal deletion and a much rarer proximal interstitial deletion spanning the 18q11.2-q21.1 region.

**Methods:** We report two new patients and review 27 additional cases in DECIPHER/ClinGen databases and four cases from the literature, with more proximal 18q deletions involving 18q11-q12 (band 1 only; 17.2–43.5 Mb position) deletion.

**Results:** Common presentations of 18q11-q12 deletions include developmental delay/intellectual disability (DD/ID) (82%); speech delay/autism/attention deficit and hyperactivity/other behavioral problems (30%); conotruncal heart defects (15%); and subtle/non-specific facial dysmorphism. The deletion in four out of five cases with cardiac defect was distal to *GATA6*, suggesting an alternative mechanism other than haploinsufficiency of *GATA6* as an underlying cause of cardiac malformations. Precocious puberty with advanced skeletal age was first observed in one patient, suggesting a unique and expanded phenotype of proximal 18q deletion. When

This is an open access article under the terms of the Creative Commons Attribution-NonCommercial-NoDerivs License, which permits use and distribution in any medium, provided the original work is properly cited, the use is non-commercial and no modifications or adaptations are made.

© 2019 The Authors. *Molecular Genetics & Genomic Medicine* published by Wiley Periodicals, Inc.

comparing genotype–phenotype correlations from the present study with previous reports, the critical regions for selected phenotypes of 18q11–q12 deletion syndrome could be narrowed down as follows: 38.8–43.5 Mb for moderate to severe DD/ID, 19.6–24.4 Mb and 26.9–28.6 Mb for conotruncal heart defect.

**Conclusion:** The detailed clinical delineation of the proximal 18q deletions identified in this study should contribute to better understanding of the genotype–phenotype correlations and better long-term care of patients with this rare syndrome.

#### KEYWORDS

18q11–q12 microdeletion, autism, chromosomal microarray, conotruncal heart defects, *GATA6*, intellectual disability

## 1 | INTRODUCTION

Chromosome 18q deletion syndrome (OMIM 601808) is characterized by mental retardation, microcephaly, short stature, congenital aural atresia, foot deformities, hypotonia, and delayed myelination (Cody et al., 1999; Feenstra et al., 2007). This disorder is rare with an estimated prevalence of 1:40,000. It is classified into proximal interstitial deletion spanning the region between the centromere and the 46-Mb position (18q11.2–18q21.1) and distal deletions spanning from the 46-Mb position to qter (18q21.1–qter) (Cody et al., 2015, 2007). Since the establishment of chromosomal microarrays (CMA) in clinical practice, many genotype–phenotype correlations have been further elucidated. Most patients with partial 18q deletion present with the distal deletions, and the 18q22.3–18q23 region has been determined as critical for the development of classic phenotypes (Cody et al., 1999, 2015; Feenstra et al., 2007). Proximal interstitial deletions however are relatively rare; nearly all such reports have involved the 18q12 region and patients usually present with short stature, behavioral problems, autism, speech delay, and cleft palate (Buisse et al., 2008; Cody et al., 2007; Feenstra et al., 2007; McEntagart et al., 2001). Until now, there have been very few reports of 18q11.2 deletion, making it difficult to define clinical characteristics of the more proximal deletion of 18q. Cody et al. (2007), Feenstra et al. (2007) have reported patients with large 18q deletions that overlap the 18q11.2 region and attempted to delineate the clinical phenotypes. So far no deletions have been identified in the region close to the centromere (chr18q11.1:17,200,001–19,000,000; hg19), as such deletions are likely to be lethal (Cody et al., 2015). A patient with 18q11.2 deletion of 4.7 Mb involving *GATA6*, a cardiac malformation-associated gene, was first reported by Bui et al. (2013); the deleted region (19,667,062–24,401,876; hg19) is distally adjacent to the above-mentioned region. In this study, to further delineate the clinical phenotypes, we report two new patients with 18q11–q12 deletions not involving *GATA6*, and uncover 27 additional patients in the Database of Chromosomal Imbalance and Phenotype in Humans using Ensembl Resources (DECIPHER) and ClinGen database.

## 2 | CLINICAL REPORT

### 2.1 | Patients

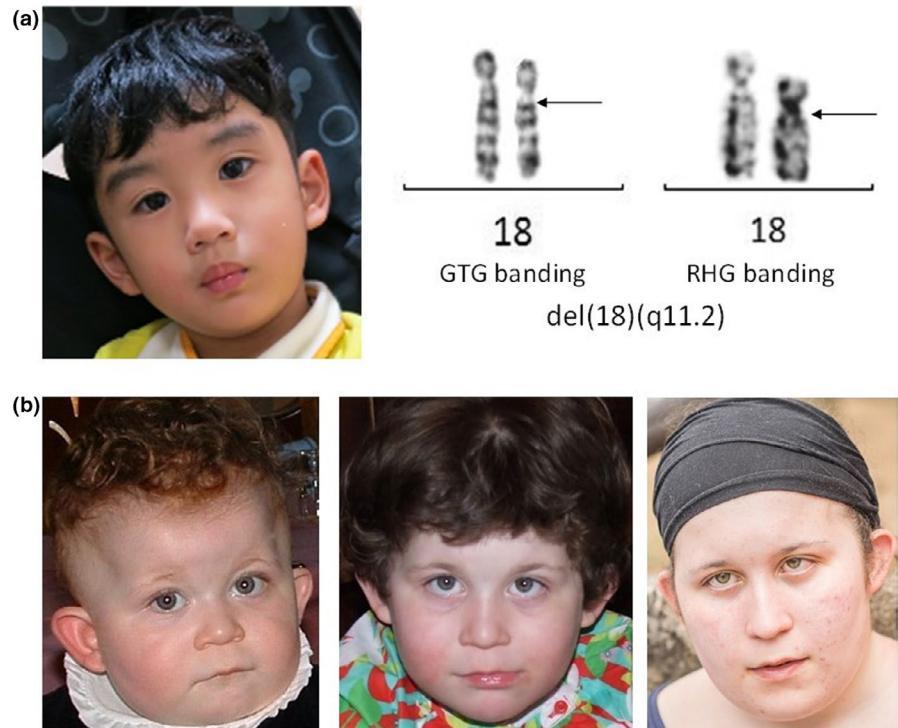Our study was approved by the Human Research Ethics Committee of the Faculty of Medicine, Thammasat University No.1 (MTU-EC-PE-0-061/62) and the Faculty of Medicine Ramathibodi Hospital, Mahidol University (ID12-57-03; MURA2019/291).

Patient 1 is the first child of a non-consanguineous Thai couple. He was born by normal delivery following an uneventful pregnancy, at 37 weeks of gestation, with birth weight of 2,550 g (10th centile), length of 50 cm (50th–75th centile), and head circumference (HC) of 30 cm (3rd centile) and Apgar scores of 9 and 10 at 5 and 10 min, respectively. Briefly after birth, he was found to have cyanosis and congestive heart failure due to truncus arteriosus, atrial septal defect, ventricular septal defect, and truncal valve regurgitation. At 6 weeks, he was referred to Thammasat University Hospital and underwent Modified Blalock–Taussig shunt and pulmonary artery banding, followed by corrective surgery at 10 months. Bilateral vesicoureteral reflux grade V was detected using ultrasonography.

Developmentally, he started walking unassisted at 12 months, talking at 18 months. At 30 months, he could walk, run, build four blocks vertically, follow simple commands, and say 3–5 words, indicating developmental delay (DD) equivalent to those of an 18-month-old child. Physical examination revealed a weight of 11.6 kg (10th–25th centile), height of 92 cm (50th–75th centile), and HC of 48 cm (25th centile). He had thick eyebrows, widely spaced eyes, low-set and protruding ears, broad nasal tip, mild micrognathia, and high-arched palate (Figure 1a). His neck, chest, nipples, abdomen, and extremities were normal. His karyotype was normal (46,XY), and fluorescent in situ hybridization (FISH) for 22q11.2 deletion was negative.

After obtaining a written informed consent, CMA was performed on genomic DNA using single nucleotide polymorphism array (Illumina Infinium CytoSNP-850K BeadChip) and analyzed using BlueFuse Multi software v4.1. The Database of Genomic Variants and the Thai CNV

**FIGURE 1** (a) Patient 1. Facial profile at age 3 years (left panel). Chromosome 18 at 550-band level resolution, with Giemsa (G) and reverse (R)-banding (right panel). (b) Patient 2. Facial profile at age 1 year and 4 years (left and middle panel, respectively). Metaphase FISH analysis confirming the 18q11.2-18q12.1 microdeletion (right panel). FISH, fluorescent in situ hybridization



database (Suktitipat et al., 2014) were used to exclude common structural variations in the Thai population. The results of CMA revealed a 7.4-Mb heterozygous deletion of 18q11.2-18q12.1 [Chr18:19,886,814–27,306,978; GRCh37/hg19]. Subsequently, high-resolution (at least 550-band level) karyotype analysis of metaphase spreads, and GTG and RHG bandings were performed in trio samples, which confirmed a de novo origin of the deletion (Figure 1a).

Patient 2, the first child of a non-consanguineous Italian couple, was born at 37 weeks of gestation, via caesarian section due to maternal preeclampsia. Birth parameters included weight of 2,400 g (<10th centile), length of 45 cm (3rd–10th centile), and HC of 34 cm (5th centile). After birth she was diagnosed with atrial septal defect and interrupted aortic arch, type A (isthmus coarctation). At one month, she underwent surgery to repair the coarctation, and mitral papillary muscle dysplasia with mild stenosis was detected. Abdominal ultrasound and cerebral magnetic resonance imaging were normal. Her psychomotor development was delayed, with her first words and walking at 17–18 months. At the age of 8 years, she spoke in simple phrases and followed simple commands. She had poor concentration, hyperactivity, and distractibility. Intelligence quotient test using the Wechsler Intelligence Scale for Children–Revised was 52, indicating mild intellectual disability (ID) according to the DSM-V criteria. At the age of 9, she had precocious puberty with advanced skeletal age of 12 years.

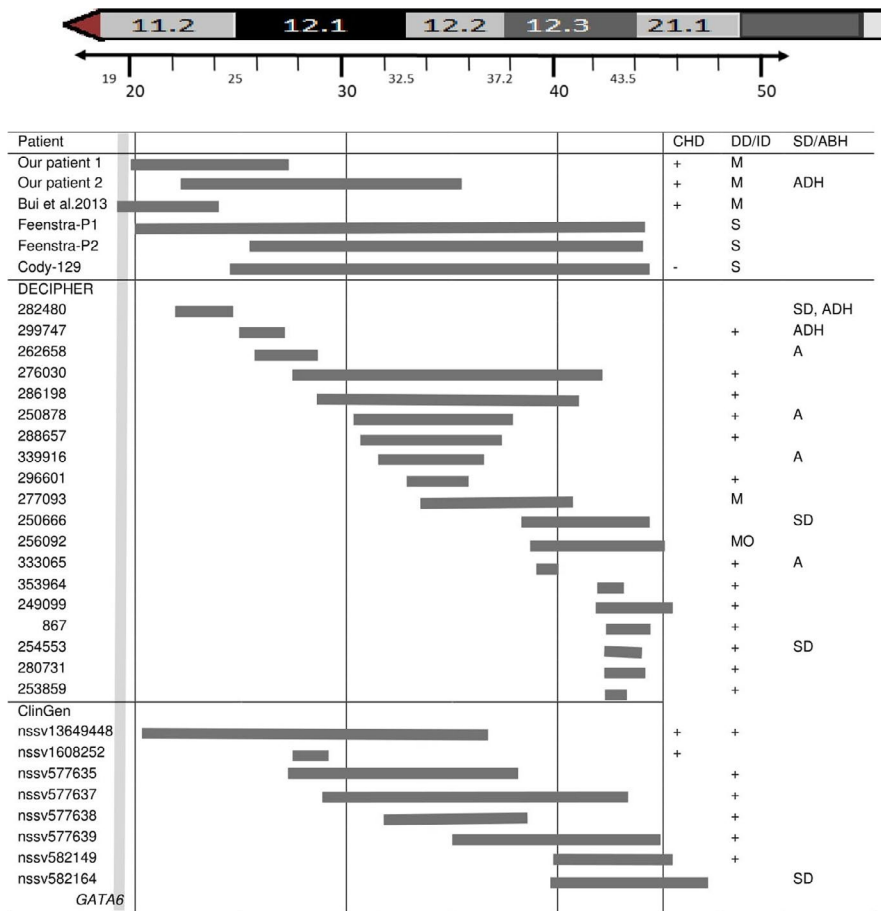
Genetic evaluation was performed at the University School of Medicine, Messina when she was 6 years old. Her growth parameters included weight of 31 kg (97th centile), length of

123 cm (97th centile), and HC of 52.8 cm (90th centile). She had brachyplagiocephaly, widely spaced eyes, strabismus, low nasal bridge, smooth philtrum, thin lip, high-arched palate, and low-set ears with hypoplastic lobules (Figure 1b). Additional features were proximally placed thumbs, scoliosis with pelvic anteversion, hypoplasia of the left femoral head, and joint laxity. She also exhibited clumsiness and difficulties with oculomotor coordination. She had neither seizure nor tremor. Her karyotype was normal (46,XX), FISH analyses for 22q11.2 and 7q11.2, and sequencing of *PTPN11* were all negative.

Following a written informed consent given, array comparative genomic hybridization (array-CGH) analysis was performed on genomic DNA, using Agilent platform (4x180K oligonucleotide array; Agilent Technologies), and analyzed using Agilent Cytogenomics software. The aCGH revealed a 13.4 Mb heterozygous interstitial deletion of 18q11.2-18q12.2 [Chr18:22,032,122–35,430,900; GRCh37/hg19]. The aberration was confirmed to be de novo using FISH analysis, using locus-specific BAC probe (RP11-369F6 at 18q12.1 from 32 K library, BACPAC Resources) (data not shown). This patient was originally DECIPHER case#260121 that we were able to contact for further investigation.

## 2.2 | Additional patients from curated database and literature review

In an attempt to further delineate clinical phenotypes of comparatively more proximal interstitial deletion of 18q, namely 18q11-18q12 (band 1 only), we performed a review of literature and curated databases, DECIPHER and ClinGen. We



**FIGURE 2** Genomic locations of the 33 cases who have 18q11-q12 microdeletions with or without *GATA6* deletion. Only patients with deletion larger than 1 Mb in size are depicted. The ruler shows Mb position relative to the chromosome bands/sub-bands. The genomic coordinates are based on genome build hg19/GRCh37. A, autism; ABH, abnormal behavior; ADH, attention deficit hyperactivity; CHD, congenital heart disease; DD, developmental delay; ID, intellectual disability; +, present; M, mild; MO, moderate; S, severe; SD, speech delay

identified four cases in the literature, including patients #1 and #2 described by Feenstra et al. (2007), patient #129 from Cody et al. (2007), and a single patient reported by Bui et al. (2013). As for the curated databases, to ensure that only patients with clinically significant CNV spanning chromosome 18q11q12 region were analyzed, the inclusion criteria were as follows; deletion size >1 Mb, no larger CNVs or pathogenic CNV identified in other chromosomes, sufficient clinical data available. Twenty-seven cases were subsequently identified for further analysis, consisting of 19 and eight cases from DECIPHER and ClinGen database, respectively. Comparisons of the phenotypes and overlapping genomic locations (hg19) of the 33 cases with 18q11-q12 deletions are summarized in Figure 2, Tables S1 and S2.

### 3 | DISCUSSION

By analyzing the 33 cases, we identified common clinical phenotypes of 18q11-q12 microdeletion, which were DD/ID (27/33 or 82%), behavioral disorders including speech delay, autism and attention deficit and hyperactivity disorder (ADH)/other behavioral problems (10/33 or 30%), congenital heart defect (5/33 or 15%), and subtle/

non-specific facial abnormality. Our data are consistent with the initial report of 18q11.2 microdeletion syndrome (Bui et al., 2013). As for other malformations, there were abnormalities of kidney/renal collecting system, teeth abnormalities, syndactyly and/or overlapping fingers/toes, and eye abnormalities.

Our two patients were initially thought to have 22q11 deletion due to the presence of conotruncal heart defects, DD, and abnormal auricles. Retrospectively, their lack of other characteristics of 22q11 microdeletion syndrome such as narrow palpebral fissures, bulbous/square nose, and cleft palate/nasopharyngeal insufficiency could be considered the points for differential diagnosis. Notably, precocious puberty with advanced skeletal age found in our patient 2 is first described in proximal 18q deletion, suggesting a unique and expanded phenotype. Congenital heart defects in all five cases were in the spectrum of conotruncal malformations, which may represent the unique finding of cardiac anomaly in 18q11-q12 microdeletion. The presence of conotruncal heart defect in ClinGen patient nssv1608252 with the proximal breakpoint distal to 26.9 Mb (chr18:26,945,022-28,816,268; hg19) suggests that, in addition to the previously described proximal 19.6–24.4 Mb region containing *GATA6* (Bui et al., 2013), the distal 26.9–28.8 Mb region identified in this patient is also likely responsible

for cardiac anomalies (Figure 2). Interestingly, the deletions in patients 1 and 2, nssv13649448 and nssv1608252 from ClinGen were distal to *GATA6* (Suzuki et al., 2014), and yet, they still presented with a complex cardiac defect. Hence, cardiac anomalies in 18q11-18q12 microdeletion syndrome may not be simply explained by the haploinsufficiency of *GATA6*. Our findings suggest the possible existence of *GATA6*'s cis-regulatory elements in proximal 18q region. Further functional study is needed to clarify this observation.

Of note, we could not confirm if those 6/33 cases without DD/ID were truly with no DD/ID or owing to incomplete information deposited, as detailed data in the curated databases were barely available for comparison. The severity of DD/ID in 18q deletion was previously described as severe (Feenstra et al., 2007); however, it was mild in our and Bui's patients. Feenstra et al. has proposed the 25.2–61.4 Mb position as the critical region for severe DD/ID in 18q deletion syndrome. Notably, the deletions identified in our and Bui's cases are more proximally located and smaller compared with those with severe DD/ID previously reported (Feenstra et al., 2007). We noticed that all the patients with moderate to severe DD/ID had deletion breakpoints distal to 38.8 Mb, as defined by the proximal breakpoint of DECIPHER patient 256,092. The data suggest that the 25.2–38.8 Mb region may not be significantly associated with moderate to severe DD/ID, and that the critical region on chromosome 18q11-q12 for moderate to severe DD/ID could be reduced to 38.8–43.5 Mb position.

Interestingly, language/behavioral problems including speech delay (4/33), autism (4/33), and attention deficit/hyperactivity (3/33) are common features, accounting for 30% of cases. It has been shown that children with autism/ADH are at-risk of having psychiatric disorder(s) as an adult (Zavala et al., 2010). Therefore, a long-term follow up of patients with proximal 18q11-q12 microdeletion especially those with autism/ADH is necessary for the surveillance of possible neuropsychiatric disorder as a late-onset comorbidity. Moreover, a number of genes in 18q11-18q12 region with no known disease-causing information should be further explored for potential connection with neurodevelopmental disorders.

Dysmorphic features are present with subtle or nonspecific pattern, in most cases analyzed in the present study. These findings again emphasize the variable expressivity nature of this rare syndrome which complicates prediction of the clinical phenotypes. Therefore, we agree with Cody et al. (2015) that a genotype-based approach for 18q deletion should be used for the prognostic purpose and planning for management of individual patients.

Multiple genes listed in HGNC (HUGO Gene Nomenclature Committee)/OMIM databases were found deleted in patients 1 and 2, but only five and 12 genes are known to be disease-causing (Table S1). Among these, only *KCTD1*, *ASXL3*, *DTNA*, *TTR*, and *MAPRE2* are predicted to be heterozygous

disease-causing genes with autosomal dominant inheritance. Mutations of *KCTD1*, a transcription repressor, lead to scalp-ear-nipple syndrome, with incomplete penetrance. All reports of this syndrome were caused by missense mutations (Marneros et al., 2013), which might explain why patients with heterozygous *KCTD1* deletion including patients 1 and 2 did not manifest the phenotypes. Mutations of *DTNA*, a gene encoding dystrobrevin muscle protein, are associated with left ventricular noncompaction of variable age of onset and with/without the presence of a congenital cardiac defect (Ichida et al., 2001). Therefore, routine echocardiogram monitoring may be necessary for patient 2. The other 10 OMIM disease-causing genes within the deleted region are autosomal recessive; hence, the phenotype would only present when both alleles are mutated. However, patient 1 is still young, there are data suggesting that additional phenotypes may become apparent with time. Heterozygous carriers of mutations in *NPC1* that cause Niemann-Pick type C by a recessive mechanism can have adult onset motor or anxiety disorders (Hung et al., 2016; Lamri, Pigeyre, Garver, & Meyre, 2018), and hemizyosity of *LAMA3* can cause enamel pitting of secondary dentition (Gostynska et al., 2016). In addition, other OMIM genes included in the deletions have also been shown to be associated with specific phenotypes. Heterozygous loss of function variants of *OSBPL1A* are associated with low plasma high density lipoprotein cholesterol levels and impaired cholesterol efflux capacity (Motazacker et al., 2016), therefore our patient 1 may benefit from a lipid profile screening. Of note, there is a hemizyosity of *ZNF24* in patient 2, which is associated with seizures and tremors (Cody et al., 2015), but these features are not seen in our patient.

In conclusion, common clinical features of 18q11-q12 microdeletion were mild DD/ID, autism/ADH and behavioral problem, conotruncal heart defect, and subtle facial dysmorphisms. The genetic mechanism underlying the associated cardiac defect is not exclusively due to haploinsufficiency of *GATA6* and required further study. 18q11-q12 is a potential candidate region for studying autism and abnormal behavior-related genes. Our findings contribute to a better clinical delineation and long-term care for this rare group of patients and enhance the understanding of the genetic mechanism underlying its related phenotypes.

## ACKNOWLEDGMENTS

We thank the patients and their families for participating in this study, the DECIPHER consortium and ClinGen for the use of generated data. This work was supported by grants from the Development Potential of the Thai People Project, Faculty of Medicine Ramathibodi Hospital, Mahidol University (NJ). DW, NJ, and TT are recipients of the Research Career Development Awards from the Faculty of Medicine at Ramathibodi Hospital. We thank Natasha

Beeton-Kempen, PhD, from Edanz Group ([www.edanzediting.com/ac](http://www.edanzediting.com/ac)) for editing a draft of this manuscript.

## CONFLICT OF INTEREST

The authors have no conflict of interest to declare.

## ORCID

Kitiwan Rojnueangnit  <https://orcid.org/0000-0002-9488-4470>

Thipwimol Tim-Aroon  <https://orcid.org/0000-0001-8044-7993>

## REFERENCES

- Bui, P. H., Dorrani, N., Wong, D., Perens, G., Dipple, K. M., & Quintero-Rivera, F. (2013). First report of a de novo 18q11.2 microdeletion including GATA6 associated with complex congenital heart disease and renal abnormalities. *American Journal of Medical Genetics Part A*, *161A*(7), 1773–1778. <https://doi.org/10.1002/ajmg.a.35974>
- Buysse, K., Menten, B., Oostra, A., Tavernier, S., Mortier, G. R., & Speleman, F. (2008). Delineation of a critical region on chromosome 18 for the del(18)(q12.2q21.1) syndrome. *American Journal of Medical Genetics Part A*, *146A*(10), 1330–1334. <https://doi.org/10.1002/ajmg.a.32267>
- Cody, J. D., Davis Ghidoni, P., DuPont, B. R., Hale, D. E., Hilsenbeck, S. G., Stratton, R. F., ... Kaye, C. I. (1999). Congenital anomalies and anthropometry of 42 individuals with deletions of chromosome 18q. *American Journal of Medical Genetics*, *85*(5), 455–462. [https://doi.org/10.1002/\(SICI\)1096-8628\(19990827\)85:5<455::AID-AJMG5>3.0.CO;2-Z](https://doi.org/10.1002/(SICI)1096-8628(19990827)85:5<455::AID-AJMG5>3.0.CO;2-Z)
- Cody, J. D., Sebold, C., Heard, P., Carter, E., Soileau, B., Hasi-Zogaj, M., ... Hale, D. E. (2015). Consequences of chromosome 18q deletions. *American Journal of Medical Genetics Part C: Seminars in Medical Genetics*, *169*(3), 265–280. <https://doi.org/10.1002/ajmg.c.31446>
- Cody, J. D., Sebold, C., Malik, A., Heard, P., Carter, E., Crandall, A. L., ... Hale, D. E. (2007). Recurrent interstitial deletions of proximal 18q: A new syndrome involving expressive speech delay. *American Journal of Medical Genetics Part A*, *143A*(11), 1181–1190. <https://doi.org/10.1002/ajmg.a.31729>
- Feenstra, I., Vissers, L. E., Orsel, M., van Kessel, A. G., Brunner, H. G., Veltman, J. A., & van Ravenswaaij-Arts, C. M. (2007). Genotype-phenotype mapping of chromosome 18q deletions by high-resolution array CGH: An update of the phenotypic map. *American Journal of Medical Genetics Part A*, *143A*(16), 1858–1867. <https://doi.org/10.1002/ajmg.a.31850>
- Gostynska, K. B., Yan Yuen, W., Pasmooij, A. M., Stellingsma, C., Pas, H. H., Lemmink, H., & Jonkman, M. F. (2016). Carriers with functional null mutations in LAMA3 have localized enamel abnormalities due to haploinsufficiency. *European Journal of Human Genetics*, *25*(1), 94–99. <https://doi.org/10.1038/ejhg.2016.136>
- Hung, Y. H., Walterfang, M., Churilov, L., Bray, L., Jacobson, L. H., Barnham, K. J., ... Bush, A. I. (2016). Neurological dysfunction in early maturity of a model for Niemann-Pick C1 carrier status. *Neurotherapeutics: the Journal of the American Society for Experimental NeuroTherapeutics*, *13*(3), 614–622. <https://doi.org/10.1007/s13311-016-0427-5>
- Ichida, F., Tsubata, S., Bowles, K. R., Haneda, N., Uese, K., Miyawaki, T., ... Towbin, J. A. (2001). Novel gene mutations in patients with left ventricular noncompaction or Barth syndrome. *Circulation*, *103*(9), 1256–1263. <https://doi.org/10.1161/01.cir.103.9.1256>
- Lamri, A., Pigeyre, M., Garver, W. S., & Meyre, D. (2018). The extending spectrum of NPC1-related human disorders: From Niemann-Pick C1 disease to obesity. *Endocrine Reviews*, *39*(2), 192–220. <https://doi.org/10.1210/er.2017-00176>
- Marneros, A. G., Beck, A. E., Turner, E. H., McMillin, M. J., Edwards, M. J., Field, M., ... Bamshad, M. J. (2013). Mutations in KCTD1 cause scalp-ear-nipple syndrome. *American Journal of Human Genetics*, *92*(4), 621–626. <https://doi.org/10.1016/j.ajhg.2013.03.002>
- McEntagart, M., Carey, A., Breen, C., McQuaid, S., Stallings, R. L., Green, A. J., & King, M. D. (2001). Molecular characterisation of a proximal chromosome 18q deletion. *Journal of Medical Genetics*, *38*(2), 128–129. <https://doi.org/10.1136/jmg.38.2.128>
- Motazacker, M. M., Pirhonen, J., van Capelleveen, J. C., Weber-Boyvat, M., Kuivenhoven, J. A., Shah, S., ... Oikkonen, V. M. (2016). A loss-of-function variant in OSBPL1A predisposes to low plasma HDL cholesterol levels and impaired cholesterol efflux capacity. *Atherosclerosis*, *249*, 140–147. <https://doi.org/10.1016/j.atherosclerosis.2016.04.005>
- Suktitipat, B., Naktang, C., Mhuantong, W., Tularak, T., Artiwet, P., Pasomsap, E., ... Jinawath, N. (2014). Copy number variation in Thai population. *PLoS ONE*, *9*(8), e104355. <https://doi.org/10.1371/journal.pone.0104355>
- Suzuki, S., Nakao, A., Sarhat, A. R., Furuya, A., Matsuo, K., Tanahashi, Y., ... Azuma, H. (2014). A case of pancreatic agenesis and congenital heart defects with a novel GATA6 nonsense mutation: Evidence of haploinsufficiency due to nonsense-mediated mRNA decay. *American Journal of Medical Genetics Part A*, *164*(2), 476–479. <https://doi.org/10.1002/ajmg.a.36275>
- Zavala, J., Ramirez, M., Medina, R., Heard, P., Carter, E., Crandall, A. L., ... Escamilla, M. (2010). Psychiatric syndromes in individuals with chromosome 18 abnormalities. *American Journal of Medical Genetics Part B: Neuropsychiatric Genetics*, *153b*(3), 837–845. <https://doi.org/10.1002/ajmg.b.31047>

## SUPPORTING INFORMATION

Additional supporting information may be found online in the Supporting Information section at the end of the article.

**How to cite this article:** Rojnueangnit K, Charalsawadi C, Thammachote W, et al. Clinical delineation of 18q11-q12 microdeletion: Intellectual disability, speech and behavioral disorders, and conotruncal heart defects. *Mol Genet Genomic Med*. 2019;7:e896. <https://doi.org/10.1002/mgg3.896>