


Provided for non-commercial research and education use.  
Not for reproduction, distribution or commercial use.



This article appeared in a journal published by Elsevier. The attached copy is furnished to the author for internal non-commercial research and education use, including for instruction at the authors institution and sharing with colleagues.

Other uses, including reproduction and distribution, or selling or licensing copies, or posting to personal, institutional or third party websites are prohibited.

In most cases authors are permitted to post their version of the article (e.g. in Word or Tex form) to their personal website or institutional repository. Authors requiring further information regarding Elsevier's archiving and manuscript policies are encouraged to visit:

<http://www.elsevier.com/authorsrights>

## Systematic Review Dental Implants

# Immediate versus delayed positioning of dental implants in guided bone regeneration or onlay graft regenerated areas: a systematic review

**M. Clementini, A. Morlupi,  
 C. Agrestini, A. Barlattani**

Department of Dentistry, University "Tor Vergata", Rome, Italy

*M. Clementini, A. Morlupi, C. Agrestini, A. Barlattani: Immediate versus delayed positioning of dental implants in guided bone regeneration or onlay graft regenerated areas: a systematic review. Int. J. Oral Maxillofac. Surg. 2013; 42: 643–650. © 2013 International Association of Oral and Maxillofacial Surgeons. Published by Elsevier Ltd. All rights reserved.*

**Abstract.** The aim of this study was to compare success rates in immediate and delayed dental implant placement following guided bone regeneration or onlay bone block ridge augmentation. A systematic review of all studies on this topic was performed. For inclusion, studies had to involve at least five patients, report specific success criteria, and have a minimum follow-up period of 6 months. Studies reporting only the survival rate of implants were excluded. From 287 studies identified, 79 were screened and 13 were included in the analysis. Six studies provided data on simultaneous (immediate) positioning of implants, five studies on delayed positioning, and two studies provided data on both of these approaches. Success rates for implants placed using a simultaneous approach ranged from 61.5% to 100%; success rates for implants placed using a staged approach ranged from 75% to 98%. Even though the current review revealed that there are not many studies reporting data relevant to the analyzed topic, the data obtained suggest that the delayed positioning of implants should be considered more predictable than the immediate positioning. Studies presenting a control group and adopting standardized success criteria are required, and data from this review must be considered indicative.

Accepted for publication 24 January 2013  
 Available online 6 March 2013

The dental rehabilitation of partially or totally edentulous patients with osseointegrated oral implants is nowadays one of the most successful methods to restore oral aesthetics and function, with predictable

results.<sup>1–9</sup> However, a minimum amount of bone width and height is an essential prerequisite for the correct placement of oral implants. Thus, unfavourable local conditions due to atrophy, trauma, and

periodontal disease, may result in insufficient bone volume or an unfavourable inter-arch relationship, which will not allow the correct and prosthodontically guided positioning of dental implants.

For such cases, many different techniques have been developed to reconstruct the deficient alveolar jaws for the placement of dental implants.<sup>10–13</sup>

Further, the ideal timing of implant placement after dental extraction has been extensively discussed in the literature, and advantages and disadvantages have been attributed to the different protocols<sup>14,15</sup>: (1) immediate or type 1, when the implant is placed during the same surgical intervention as the dental extraction; (2) early implant placement or type 2, when implants are placed during the early stages of healing (from 4 to 8 weeks); and (3) delayed implant placement or type 3, when implants are placed when the ridge has healed (from 3 to 6 months). The timing of implant placement after reconstruction of atrophic alveolar ridges instead, also remains a controversial topic.

In fact implants can be positioned in conjunction with grafting procedures (one-stage surgery or immediate implant placement) or after a consolidation period (two-stage surgery or delayed implant placement). Although it is difficult to determine a clear indication for immediate or delayed implant placement, the majority of authors suggest immediate implant placement when the residual alveolar bone presents adequate quality and quantity<sup>10</sup>. In fact, the primary stability of dental implants, which is considered to be the essential condition for osseointegration, is closely related to these parameters.

Through the years, many studies proposing the two different approaches have appeared in the scientific literature. According to the authors who support immediate implant placement,<sup>16–28</sup> the reason is that the resorption of grafted bone over time is not a linear process but most pronounced soon after its transplantation.<sup>29</sup> Those who advocate delayed placement<sup>30–39</sup> instead, affirm that immediate placement of implants exposes the patient to some risks, such as partial or total loss of the graft in the case of wound dehiscence, membrane or onlay graft exposure and/or infection, and non-integration of implants related to the immediate placement into avascular bone. In fact, when a delayed protocol is performed, it would be possible to place implants in a revascularized graft. Since the regenerative capacity of bone is determined by the presence of vessels, bone marrow, and vital bone surfaces, a delayed approach would permit a better integration of implants (higher values of bone–implant contact) and stability of implants as compared with immediate implant placement.<sup>31,40,41</sup>

The aim of this study was to compare, in a systematic manner, publications reporting the success rate of dental implants placed simultaneously or as a second surgery following ridge augmentation by means of guided bone regeneration (GBR) or onlay graft regeneration technique.

## Materials and methods

Inclusion and exclusion criteria were defined by the authors, before beginning the study, according to the protocol outlined below.

For inclusion, publications had to be based on human subjects and written in English, and had to analyze the success rate of endosseous implants placed in augmented jaws by means of GBR or onlay graft technique, specifying the type of implant surgery (simultaneous or staged) with the respective results. Every study design (prospective and retrospective) was accepted, but studies had to involve more than five healthy patients and report on implant success with at least 6 months of loading, in order to observe biological complications during function rather than early implant failures.

Publications that reported the same data as reported in later publications by the same authors were not considered. Studies describing only the results of bone augmentation, only the survival rate of implants, and those without any specified success criteria, were excluded. Studies on major maxillofacial reconstruction following tissue resection in the case of tumours and bone defects related to congenital malformations (such as cleft lip and palate or major craniofacial malformations), as well as socket preservation techniques or the treatment of peri-implantitis were not included.

The following augmentation procedures were considered: (1) GBR, according to the biological principle of a protected space, created with a resorbable or non-resorbable barrier membrane over the area to be augmented, in order to stabilize the blood clot and to exclude soft tissue penetration<sup>42,43</sup>; and (2) bone block grafts, according to an onlay graft technique, used alone or associated with particulate bone, and covered or not by a resorbable membrane.<sup>10</sup>

Even if studies did not adopt the same criteria, implant success was the main outcome, and it had to be well-specified in the publications for inclusion. However, when possible, the following clinical and radiographic criteria were utilized to define implant success based on a combination

of the success criteria previously defined by Albrektsson et al.<sup>2</sup> and adapted by Buser et al.<sup>5</sup>: absence of mobility, absence of persistent subjective complaints (pain, foreign body sensation and/or dysesthesia), absence of recurrent peri-implant infection with suppuration, absence of a continuous radiolucency around the implant,<sup>44</sup> and absence of a pocket probing depth (PPD) >5 mm.<sup>45</sup> Even if during the first year of function 1.5 mm of vertical bone resorption was accepted, after that time, the annual vertical bone loss should not exceed 0.2 mm (mesially or distally).<sup>2,46</sup>

The search strategy incorporated a search of electronic databases, supplemented by cross-checking of the bibliographies of relevant review articles. A search on MEDLINE and EMBASE was conducted up to January 2010 in accordance with the Preferred Reporting Items Systematic review and Meta-Analyses (PRISMA) statement,<sup>47</sup> using a combination of medical subject heading (MeSH) terms and text words: “Implants”, “Dental Implants”, “Osseointegrated Implants”, “Oral Implants”, “Implant Supported Prosthesis”, “Transmucosal Implants”, “Alveolar Ridge Augmentation”, “Lateral Ridge Augmentation”, “Alveolar Ridge Atrophy”, “Regeneration”, “Bone Regeneration”, “Guided Bone Regeneration”, “Guided Tissue Regeneration”, “Barrier Membranes”, “Membranes”, “Bone Substitutes”, “Autogenous Bone Grafts”, “Allograft”, “Xenograft”, “Calvarial Bone Graft”, “Iliac Crest Graft”, “Chin Bone Grafts”, “Onlay Bone Grafts”, “Implant Outcomes”, “Success Rate”, “Simultaneous Positioning”, “Staged Approach”, “Immediate”, “Delayed”. To exclude some non-relevant studies, “NOT (“trauma” OR “tumour” OR “injuries” OR “cancer” OR “animal”))” was added to the search.

A three-stage (Fig. 1) screening process was performed independently by two reviewers (MC and AM).

At first, all the titles were screened to eliminate irrelevant publications, review articles, and animal studies; then, all abstracts of publications selected during the first screening were analyzed, and studies were excluded on the basis of the number of patients, the intervention, and the outcome characteristics. In the last stage, through an analysis of the whole selected full texts, study eligibility was based on the predetermined inclusion and exclusion criteria. Any disagreements between the two reviewers were resolved after additional discussion with a third reviewer (CA). The inter-reviewer

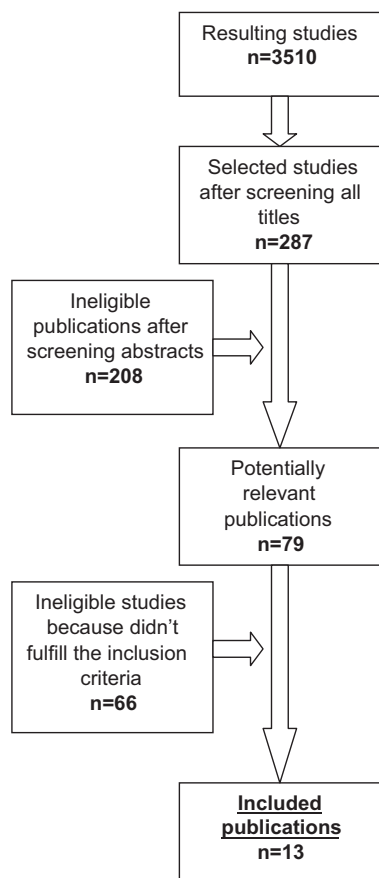


Fig. 1. Flow diagram showing study selection for the review.

reliability of the data extraction was calculated by determining the percentage of agreement and the correlation coefficients with a kappa analysis.

A table was created to organize the data from all the included studies (Table 1) and the results were discussed.

## Results

The preliminary investigation resulted in 3510 titles. Following the first stage of screening (titles), 287 potentially relevant studies were identified, and then, after second-stage screening (abstracts), 79 full-text publications were obtained and analyzed. Finally, 13 articles were found to fulfil the inclusion criteria. Agreement in study selection between reviewers was 89.53% (kappa value = 0.46).

Because of the absence of appropriate randomized controlled trials (RCTs) and controlled clinical trials (CCTs), this systematic review included only prospective and retrospective cohort studies. As such, and due also to the significant heterogeneity between studies, a meta-analysis was

not performed and the synthesis of data is described in a narrative manner.

### Ridge augmentation

Chiapasco et al.<sup>48</sup> reported the values of vertical augmentation following the positioning of bone blocks harvested from calvaria in the area of the anterior mandible (residual bone height <5 mm). The mean bone augmentation obtained after the reconstruction procedure was 8–11 mm, with a mean resorption lower than 10% at the time of implant positioning (6 months after the bone grafting surgery).

Another study by the Chiapasco et al.<sup>49</sup> provides data on the reconstruction of atrophic mandibles by means of bone blocks harvested from the mandible ramus. The mean bone gain after the procedure was 4.6 mm and the mean bone resorption before the implant positioning (4–5 months after the augmentation procedure) was 0.6 mm. After a post-loading follow-up of 1 year, the mean bone resorption was 0.3 mm, and after 2 and 4 years it was 0.9 and 1.1 mm, respectively.

In the study by Llambés et al.<sup>50</sup>, a mean vertical ridge augmentation of 3 mm in the area of posterior mandible was obtained by means of bioabsorbable membranes and a mixture of autologous and bovine bone. A complete regeneration was achieved in 24 of 32 implants, but three implants failed to show any new bone formation.

Juodzbaly et al.<sup>43</sup> also performed a vertical ridge augmentation by means of bioabsorbable membranes and bovine bone, simultaneously with the implant placement. In this case, the mean vertical defect ranged from 3.8 to 10 mm. At the time of prosthesis placement, good peri-implant defect filling (the mean distance from the implant shoulder to the alveolar bone level (DIB) = 1.69 mm) was shown, except in one case (DIB = 3.6 mm).

Van der Meij et al.<sup>28</sup> provide data on the positioning of bone blocks harvested from the iliac crest. The grafts were positioned in the atrophic anterior mandibles of 17 patients, and the mean bone gain was 8.5 mm (mean augmentation of 95%). The implants (two for each patient) were positioned simultaneously with the grafts, and the mean bone resorption after a mean post-loading follow-up period of 4 years was 15%.

In another study by Chiapasco et al.<sup>51</sup>, data on vertical GBR by means of non-resorbable expanded polytetrafluoroethylene (ePTFE) membranes and autologous bone chips, both in the maxilla and mandible, are reported. The implants were

placed simultaneously or in a second stage surgery after the GBR technique. The mean bone resorption after a 3-year post-loading follow-up was 2.06 mm for the simultaneous approach; for the staged approach, values of mean bone resorption were 1.35 mm before the implant placement and 1.69 mm after 3 years of function.

Nyström et al.<sup>27</sup> reported data on the augmentation of atrophic maxillary ridges by means of bone blocks harvested from the iliac crest in 30 consecutively treated patients. The implants (a total of 177) were inserted simultaneously with the grafts and patients were followed for an observation period of 10 years. The resorption results were higher in the first 3 years after function and became stable in the following years, without other significant losses.

Buser et al.<sup>52</sup> reported data on bone gain in the case of horizontal GBR by means of autologous bone and non-resorbable membranes. The mean bone gain was 3.5 mm at the time of implant placement (6–9 months after ridge augmentation), and a success rate (absence of mobility, absence of peri-implant radiolucency, absence of persistent subjective complaints, and absence of suppuration) of 98.3% was reported after a post-loading follow-up of 5 years.

In the study of Brunel et al.<sup>53</sup>, the bone gain obtained in 14 patients by means of GBR with resorbable collagen membranes and hydroxyapatite is reported. After a healing period of 8 months, 14 implants were placed, with a bone loss (7 years post-loading follow-up) of <2 mm in 13 of the 14 treated areas.

Chiapasco et al.<sup>33</sup> in their study, reported data on the regeneration of horizontal defects in both mandibles and maxillas. The GBR was obtained by means of non-resorbable ePTFE membranes and autologous bone chips harvested from intraoral donor sites. For mean residual bone values of 3.2 mm, a mean bone gain of 2.7 mm at the time of implant placement was reported.

Lorenzoni et al.<sup>54</sup> reported data on GBR obtained by means of ePTFE membranes in association with grafting materials, for the immediate placement of 85 implants (39 in the maxilla and 46 in the mandible). The mean recorded bone loss at 24 months after implant positioning was 1.51 mm.

Triplett and Schow<sup>30</sup>, in their study, analyzed not only the success rate of dental implants placed in grafted areas, but also the success of the augmentation procedure. Thirty-two grafts were positioned (29 harvested from the iliac crest and three from calvaria) in patients with

Table 1. Immediate versus delayed positioning of dental implants in GBR or onlay-graft regenerated areas. Characteristics of the included studies.

Ref.	Study design	Year	City	Type of augmentation	Number of patients (smokers)	Mean age, years	Implants (number/type/surface)	Area of implants	Post-loading follow-up	Restorative design	Approach	Success rate of implants	Survival rate of implants
Chiapasco <sup>48</sup>	CS	2007	Milan (Italy)	Onlay from calvaria	6 (>15 cigarettes/day excluded)	56	23/ITI (Nobel Biocare)/surface not reported	Mandible	1–3 years	Overdentures	Delayed	95.7%	100%
Chiapasco <sup>49</sup>	RPS	2007	Milan (Italy)	Onlay from mandibular ramus	8 (>15 cigarettes/day excluded)	41	19/Straumann/surface not reported	Mandible	24–48 months	Single crowns	Delayed	89.5%	100%
Llambés <sup>50</sup>	CS	2007	Valencia (Spain)	Vertical GBR	11 (all but one <10 cigarettes/day)	48	32/Osseotite (BIOMET 3i)/surface not reported	Mandible	1 year	NR	Immediate	93.75%	93.75%
Juozbalys <sup>43</sup>	CS	2007	Kaunas (Lithuania)	Vertical GBR	17 (>10 cigarettes/day excluded)	39.6	20/Osteofix/surface not reported	NR	5 years	Single crowns	Immediate	90%	100%
Van der Meij <sup>28</sup>	CS	2005	Alkmaar (Netherlands)	Onlay from iliac crest	17 (no data about smoking)	56	34/Frialit/surface not reported	Mandible	From 6 months to 7 years	Overdentures	Immediate	88.2%	–
Chiapasco <sup>51</sup>	RPS	2004	Milan (Italy)	Vertical GBR	11 (>15 cigarettes/day excluded)	NR	25/Brånemark/surface not reported	10 maxilla 15 mandible	From 29 to 41 months	NR	13 immediate 12 delayed	61.5% immediate 75% delayed	100%
Nyström <sup>27</sup>	CS	2004	Umea (Sweden)	Onlay from iliac crest	30 (no data about smoking)	53	177/NR/surface not reported	Maxilla	10 years	Full arch screw bridges	Immediate	72.8%	–
Buser <sup>52</sup>	PCS	2002	Berne (Switzerland)	Horizontal GBR	40 (no data about smoking)	NR	61/ITI/surface not reported	NR	5 years	Single crowns or fixed partial dentures	Delayed	98.3%	100%
Brunel <sup>53</sup>	CS	2001	Toulouse (France)	GBR	14 (no smokers)	48	14/NR/surface not reported	13 maxilla 1 mandible	7 years	NR	Delayed	86%	100%
Chiapasco <sup>33</sup>	CS	1999	Milan (Italy)	GBR and onlay from intra-oral sites, calvaria, iliac crest	15 (heavy smokers excluded)	NR	30/18 ITI; 12 Brånemark/surface not reported	21 maxilla 9 mandible	From 18 to 36 months	NR	Delayed	93.3%	100%
Lorenzoni <sup>54</sup>	CS	1999	Graz (Austria)	GBR	82 (no data about smoking)	21–61	85/Frialit/surface not reported	39 maxilla 46 mandible	24 months	Single crowns cemented Single crowns screw Bridges cemented Bridges screw Bars	Immediate	100%	100%
Triplet <sup>30</sup>	RS	1996	Dallas (Texas)	Onlay from ilium and cranium	NR (no data about smoking)	NR	175/NR/surface not reported	Maxilla and mandible	From 12 months	NR	65 immediate 110 delayed	84.6% immediate 88.2% delayed	–
Isaksson <sup>19</sup>	CS	1992	NR	Onlay from iliac crest	8 (all heavy smokers apart from one patient)	NR	46/Brånemark/surface not reported	Maxilla	32–64 months	Implant supported partial dentures	Immediate	83%	–

CS, case series; GBR, guided bone regeneration; NR, not reported; PCS, prospective controlled study; RPS, randomized prospective study; RS, retrospective study.

atrophic ridges. After a minimum 1-year follow-up period, five of the 32 grafts had failed, resulting in a success of the augmentation procedure of 84.3%.

#### Immediate implant placement—success and survival rate

Six studies<sup>19,27,28,43,50,54</sup> provided data on simultaneous (immediate) positioning of implants, and two studies<sup>30,51</sup> provided data on both of the approaches (immediate and delayed).

Llambés et al.<sup>50</sup>, who reported a success rate of 93.75%, described the immediate positioning of all 32 implants inserted during the study together with vertical GBR. All the implants were situated in the area of the posterior mandible, with a mean required vertical augmentation of 3.5 mm.

Juodzbalyš et al.<sup>43</sup>, referring to the positioning of 17 implants, reported a success rate of 90% after 5 years of post-loading follow-up, according to the Albrektsson criteria; the survival rate was 100%. All 17 implants were placed simultaneously with the guided bone augmentation procedure.

Van der Meij et al.<sup>28</sup> reported data on the immediate positioning of 34 implants (two for each patient) in the area of the anterior mandible simultaneously with vertical bone augmentation by means of bone blocks harvested from the iliac crest. The success rate (PPD <5 mm and absence of peri-implant radiolucency) after a mean post-loading follow-up of 4 years was 88.2%.

In the study by Chiapasco et al.<sup>51</sup>, the success rate (according to the Albrektsson criteria) of the 13 implants placed with an immediate approach in association with ePTFE membranes and autologous bone chips, was 61.5% after 3 years of function, with the majority of failures associated with the exposure of the membrane during the healing period.

In the study by Nyström et al.<sup>27</sup>, 177 implants were placed simultaneously with the augmentation procedure by means of bone blocks harvested from the iliac crest. A success rate (absence of mobility and absence of peri-implant radiolucency) of 72.8% was reported after a follow-up period of 10 years. Some failures occurred: in only three patients during the first 3 years after implant positioning, related to soft tissues traumas in the grafting area, with subsequent dehiscence during the healing period.

Lorenzoni et al.<sup>54</sup> reported data on the positioning of 85 implants placed simultaneously with the GBR procedure, after a post-loading follow-up of 24 months. The

recorded success rate (absence of mobility, absence of peri-implant radiolucency, absence of persistent subjective complaints, and absence of suppuration) was 100%.

Triplett and Schow<sup>30</sup> reported a success rate (absence of mobility, absence of peri-implant radiolucency, absence of persistent subjective complaints, and absence of suppuration) of 84.6%, referring to 65 implants inserted simultaneously with the augmentation procedure.

In the study by Isaksson et al.<sup>19</sup>, 46 implants were inserted in the atrophic maxillas simultaneously with the positioning of bone blocks harvested from the iliac crest. A success rate (absence of mobility, absence of peri-implant radiolucency, and absence of suppuration) of 83% was reported, with the majority of failures occurring in the period between the positioning of the fixtures and the positioning of the abutments.

#### Delayed implant placement—success and survival rate

Five studies<sup>48,49,51–53</sup> provided data on delayed positioning of implants, and two studies<sup>30,33</sup> provided data on both of the approaches (delayed and immediate).

Chiapasco et al.<sup>48</sup> reported a success rate (according to the Albrektsson criteria) of 95.7% and a survival rate of 100% (post-loading follow-up of 12–24 months), referring to the positioning of 23 implants inserted in a second stage surgery after bone reconstruction.

In another study by Chiapasco et al.<sup>49</sup>, data are reported on the delayed positioning (4–5 months after the vertical regeneration procedure) of 19 implants in the mandible. The success rate (according to the Albrektsson criteria) after 24–48 months of function was 89.5%, with a survival rate of 100%.

Triplett and Schow<sup>30</sup> reported a success rate (absence of mobility, absence of peri-implant radiolucency, absence of persistent subjective complaints, and absence of suppuration) of 88.2%, referring to 110 implants placed in a second stage surgery after the ridge augmentation procedure (after a healing period of 6–9 months).

In the study by Chiapasco et al.<sup>51</sup>, the success rate of 12 implants placed with a delayed approach following vertical GBR procedure by means of non-resorbable ePTFE membranes and autologous bone chips was 75%.

Buser et al.<sup>52</sup> reported a success rate (absence of mobility, absence of peri-implant radiolucency, absence of persistent subjective complaints, and absence of

suppuration) of 98.3% after 5 years of function, with a survival rate of 100%, referring to 61 implants positioned in horizontal guided bone regenerated areas.

A success rate (absence of mobility, absence of peri-implant radiolucency, absence of persistent subjective complaints, and absence of suppuration) of 86% after 7 years of function, with a survival rate of 100%, was reported by Brunel et al.<sup>53</sup>, referring to 14 implants placed in GBR areas.

In the study by Chiapasco et al.<sup>33</sup>, a success rate (according to the Albrektsson criteria) of 93.3% (survival rate of 100%) after a period of function ranging from 18 to 36 months was reported, referring to 30 implants placed in a second stage surgery following the augmentation by means of horizontal GBR technique.

According to the reported data, the success rate of implants placed using a simultaneous approach ranged from 61.5% to 100% (Llambés<sup>50</sup>: 93.75%; Juodzbalyš<sup>43</sup>: 90%; Van der Meij<sup>28</sup>: 88.2%; Chiapasco<sup>51</sup>: 61.5%; Nyström<sup>27</sup>: 72.8%; Lorenzoni<sup>54</sup>: 100%; Triplett<sup>30</sup>: 84.6%; Isaksson<sup>19</sup>: 83%), with all the studies but two reporting a success rate higher than 83%.

Success rate of implants placed using a staged approach ranged from 75% to 98.3% (Chiapasco<sup>48</sup>: 95.7%; Chiapasco<sup>49</sup>: 89.5%; Chiapasco<sup>51</sup>: 75%; Buser<sup>52</sup>: 98.3%; Brunel<sup>53</sup>: 86%; Chiapasco<sup>33</sup>: 93.3%; Triplett<sup>30</sup>: 88.2%), with all the studies but two reporting a success rate higher than 88.2%.

#### Smoking status

Only one study<sup>53</sup> did not include smokers. Two studies<sup>43,50</sup> included light smokers (<10 cigarettes/day) and four studies<sup>33,48,49,51</sup> included moderate smokers (<15 cigarettes/day), while only one study<sup>19</sup> included heavy smokers. Five studies<sup>27,28,30,52,54</sup> did not report on smoking status.

#### Discussion

The aim of this study was to compare the success rates of dental implants placed simultaneously or as a second surgery following ridge augmentation by means of GBR or onlay graft technique. Because of the absence of appropriate RCTs, this systematic review included only 13 prospective and retrospective cohort studies fulfilling the inclusion criteria, and so no meta-analysis could be performed.

Data reported in the literature seem to demonstrate that GBR and onlay graft

procedures are reliable techniques, providing sufficient bone volume to allow implant placement in the case of vertical and/or horizontal defects of partially or totally edentulous patients. Most studies demonstrated that success rates of implants placed in the augmented areas by means of GBR or onlay graft technique are similar to those reported for implants placed in pristine bone.<sup>55-59</sup>

The timing of implant placement after reconstruction of alveolar ridges by means of GBR or onlay graft technique remains a controversial topic. Implants can be positioned in conjunction with grafting procedures or after consolidation of the graft has occurred. Although it is difficult to determine a clear indication for immediate or delayed implant placement, the majority of authors suggest immediate implant placement when the residual alveolar bone presents adequate quality and quantity<sup>10</sup>. In fact, the primary stability of dental implants, which is considered to be the essential condition for osseointegration, is closely related to these parameters. However, in this review, no article recorded the attainment of a required level of primary stability as the outcome to follow for selecting an immediate or delayed implant placement.

Through the years, many studies have proposed the two different approaches. The present review suggests that in GBR and onlay grafted areas, delayed positioning of implants should be considered more predictable than immediate positioning.

The success rates of implants placed using a simultaneous approach ranged from 61.5% to 100%, with all the studies but two reporting a success rate higher than 83%. The success rates of implants placed using a staged approach ranged from 75% to 98.3%, with all the studies but two reporting a success rate higher than 88.2%.

To focus on the question of the present systematic review, it is important to define the difference between the concept of survival and that of the success rate. Sometimes implants that could be considered as 'survived' do not satisfy the essential criteria that define the success rate. The survival rate of an implant is defined as its presence in the bone into the mouth. Van Steenberghe et al.<sup>24</sup> defined the survival rate as "the proportion of implants still in place in a specific time, even if they do not have any function", i.e., implants that are not functioning and implants with a significant bone loss or with signs of radiolucency and/or inflammation are 'survived' implants. This may represent a limitation in evaluating the reliability of the onlay graft regeneration technique,

because a high implant survival rate may not correspond to the success of the technique itself, considering that an implant can remain stable and osseointegrated even if the total amount of regenerated tissue after the surgical procedure has been resorbed. This is important, for example, in cases of vertical or horizontal regeneration, because while in the first clinical situation the supporting bone all around the implant is recreated, in the latter, regeneration of only the facial aspect is required, mostly for aesthetic demand.

For these reasons, only studies reporting well-defined implant success criteria were included in this review.

Finally, it should be important to address the restorative design. In fact, even when this is not the case, bone loss during the years appears also to be related to the type of prosthetic rehabilitation (single crown, fixed partial dentures, or overdentures).

In conclusion, the present systematic review found, on average, poor methodological quality of a limited number of articles focusing on the topic. None was an RCT, which is considered to be the most appropriate type of study to test the effectiveness of interventions, because this type is less prone to the effect of bias.

Within the limits of these findings the following conclusions can be drawn: from a clinical point of view, delayed positioning of implants in GBR or onlay grafted areas should be considered more predictable than immediate positioning. In the future, in order to obtain rigorous evidence-based results, studies presenting a control group and adopting standardized criteria to define success and failure of implants placed either simultaneously or as a second surgery following ridge augmentation are required. Hence data from this review must be considered indicative.

#### Funding

None.

#### Competing interests

None.

#### Ethical approval

Not required.

#### References

1. Adell R, Lekholm U, Rockler B, Brånemark PI. A 15-year study of osseointegrated implants in the treatment of the edentulous jaw. *Int J Oral Surg* 1981;**10**:387-416.

2. Albrektsson T, Zarb G, Worthington PM, Eriksson AR. The long term efficacy of currently used dental implants: a review and proposed criteria of success. *Int J Oral Maxillofac Implants* 1986;**1**:11-25.
3. Van Steenberghe D. A retrospective multicenter evaluation of the survival rate of osseointegrated fixtures supporting fixed partial prostheses in the treatment of partial edentulism. *J Prosthet Dent* 1989;**61**:217-23.
4. Lindquist LW, Carlsson GE, Jemt TA. A prospective 15-year follow-up study of mandibular fixed prostheses supported by osseointegrated implants. Clinical results and marginal bone loss. *Clin Oral Implants Res* 1996;**7**:329-36.
5. Buser D, Mericske-Stern R, Bernard JP, Behneke A, Behneke N, Hirt HP, Belser UC, Lang NP. Long-term evaluation of non-submerged ITI implants. Part I: 8-year life table analysis of a prospective multicenter study with 2359 implants. *Clin Oral Implants Res* 1997;**8**:161-72.
6. Arvidson K, Bystedt H, Frykholm A, von Konow L, Lothigius E. Five-year prospective follow-up report of Astra Tech Implant System in the treatment of edentulous mandibles. *Clin Oral Implants Res* 1998;**9**:225-34.
7. Lekholm U, Gunne J, Henry P, Higuchi K, Linden U, Bergstrom C, van Steenberghe D. Survival of the Brånemark implant in partially edentulous jaws: a 10-year prospective multicenter study. *Int J Oral Maxillofac Implants* 1999;**14**:639-45.
8. Weber HP, Crohin CC, Fiorellini JP. A 5-year prospective clinical and radiographic study of non-submerged dental implants. *Clin Oral Implants Res* 2000;**11**:144-53.
9. Leonhardt A, Grondahl K, Bergstrom C, Lekholm U. Long-term follow-up of osseointegrated titanium implants using clinical, radiographic and microbiological parameters. *Clin Oral Implants Res* 2002;**13**:127-32.
10. Chiapasco M, Zaniboni M, Boisco M. Augmentation procedures for the rehabilitation of deficient edentulous ridges with oral implants. *Clin Oral Implants Res* 2006;**17**(Suppl. 2):136-59.
11. Aghaloo TL, Moy PK. Which hard tissue augmentation techniques are the most successful in furnishing bony support for implant placement. *Int J Oral Maxillofac Implants* 2007;**22**(Suppl.):49-70.
12. Donos N, Mardas N, Chadha V. Clinical outcomes of implants following lateral bone augmentation: systematic assessment of available options (barrier membranes, bone grafts, split osteotomy). *J Clin Periodontol* 2008;**35**(8 Suppl.):173-202.
13. Rocchietta I, Fontana F, Simion M. Clinical outcomes of vertical bone augmentation to enable dental implant placement: a systematic review. *J Clin Periodontol* 2008;**35**(8 Suppl.):203-15.

14. Chen ST, Wilson Jr TG, Hämmerle CH. Immediate or early placement of implants following tooth extraction: review of biologic basis, clinical procedures, and outcomes. *Int J Oral Maxillofac Implants* 2004;**19**(Suppl.): 12–25.
15. Fugazzotto PA, Vlassis J, Butler B. ITI implant use in private practice: clinical results with 5,526 implants followed up to 72+ months in function. *Int J Oral Maxillofac Implants* 2004;**19**:408–12.
16. Adell R, Eriksson B, Lekholm U, Brånemark PI, Jemt T. A long-term follow-up study of osseointegrated implants in the treatment of totally edentulous jaws. *Int J Oral Maxillofac Implants* 1990;**5**:347–59.
17. Jensen J, Sindet-Pedersen S. Autogenous mandibular bone grafts and osseointegrated implants for reconstruction of the severely atrophied maxilla: a preliminary report. *J Oral Maxillofac Surg* 1991;**49**:1277–87.
18. Lew D, Hinkle RM, Unhold GP, Shroyer JV, Stutes RD. Reconstruction of the severely atrophic edentulous mandible by means of autogenous bone grafts and simultaneous placement of osseointegrated implants. *J Oral Maxillofac Surg* 1991;**49**:228–33.
19. Isaksson S, Alberius P. Maxillary alveolar ridge augmentation with onlay bone-grafts and immediate endosseous implants. *J Craniomaxillofac Surg* 1992;**20**:2–7.
20. Keller EE. Reconstruction of the severely atrophic edentulous mandible with endosseous implants: a 10-year longitudinal study. *Int J Oral Maxillofac Implants* 1995;**53**: 305–20.
21. Åstrand P, Nord PG, Brånemark PI. Titanium implants and onlay bone graft to the atrophic edentulous maxilla. *Int J Oral Maxillofac Surg* 1996;**25**:25–9.
22. McGrath CJ, Schepers SH, Blijdorp PA, Hoppenreijts TJ, Erbe M. Simultaneous placement of endosteal implants and mandibular onlay grafting for treatment of the atrophic mandible. A preliminary report. *Int J Oral Maxillofac Surg* 1996;**25**:184–8.
23. Vermeeren JI, Wismeijer D, van Waas MA. One-step reconstruction of the severely resorbed mandible with onlay bone grafts and endosteal implants. A 5-year follow-up. *Int J Oral Maxillofac Surg* 1996;**25**:112–5.
24. Van Steenberghe D, Naert I, Bossuyt M, De Mars G, Calberson L, Ghyselen J, Brånemark PI. The rehabilitation of the severely resorbed maxilla by simultaneous placement of autogenous bone grafts and implants: a 10-year evaluation. *Clin Oral Invest* 1997;**1**:102–8.
25. Keller EE, Tolman DE, Eckert S. Surgical-prosthetic reconstruction of advanced maxillary bone compromise with autogenous onlay block bone grafts and osseointegrated endosseous implants: a 12-year study of 32 consecutive patients. *Int J Oral Maxillofac Implants* 1999;**14**:197–209.
26. Keller EE, Tolman DE, Eckert SE. Maxillary antral–nasal inlay autogenous bone graft reconstruction of compromised maxilla: a 12-year retrospective study. *Int J Oral Maxillofac Implants* 1999;**14**:707–21.
27. Nyström E, Ahlqvist J, Gunne J, Kahnberg KE. 10-year follow-up of onlay bone grafts and implants in severely resorbed maxillae. *Int J Oral Maxillofac Surg* 2004;**33**:258–62.
28. Van der Meij EH, Blankestijn J, Berns RM, Bun RJ, Jovanovic A, Onland JM, Schoen J. The combined use of two endosteal implants and iliac crest onlay grafts in the severely atrophic mandible by a modified surgical approach. *Int J Oral Maxillofac Surg* 2005;**34**:152–7.
29. Verhoeven JW, Ruijter J, Cune MS, Terlou M, Zoon M. Onlay grafts in combination with endosseous implants in severe mandibular atrophy: one year results of a prospective, quantitative radiological study. *Clin Oral Implants Res* 2000;**11**:583–94.
30. Triplett RG, Schow SR. Autologous bone grafts and endosseous implants: complementary techniques. *J Oral Maxillofac Surg* 1996;**54**:486–94.
31. Lundgren S, Nyström E, Nilson H, Gunne J, Lindhagen O. Bone grafting to the maxillary sinuses, nasal floor and anterior maxilla in the atrophic edentulous maxilla. *Int J Oral Maxillofac Surg* 1997;**26**:428–34.
32. Neyt LF, De Clercq CA, Abeloos JV, Mommaerts MY. Reconstruction of the severely resorbed maxilla with a combination of sinus augmentation, onlay bone grafting, and implants. *J Oral Maxillofac Surg* 1997;**55**: 1397–401.
33. Chiapasco M, Abati S, Romeo E, Vogel G. Clinical outcome of autogenous bone blocks or guided bone regeneration with e-PTFE membranes for the reconstruction of narrow edentulous ridges. *Clin Oral Implants Res* 1999;**10**:278–88.
34. Raghoebar GM, Batenburg RH, Meijer HJ, Vissink A. Horizontal osteotomy for reconstruction of the narrow edentulous mandible. *Clin Oral Implants Res* 2000;**11**:76–82.
35. Raghoebar GM, Schoen P, Meijer HJ, Stelingsma K, Vissink A. Early loading of endosseous implants in the augmented maxilla: a 1-year prospective study. *Clin Oral Implants Res* 2003;**14**:697–702.
36. Bahat O, Fontanessi RV. Efficacy of implant placement after bone grafting for three-dimensional reconstruction of the posterior jaw. *Int J Periodontics Restor Dent* 2001;**21**:221–31.
37. Bell RB, Blakey GH, White RP, Hillebrand DG, Molina A. Staged reconstruction of the severely atrophic mandible with autogenous bone graft and endosteal implants. *J Oral Maxillofac Surg* 2002;**60**:1135–41.
38. Jemt T, Lekholm U. Measurements of buccal tissue volumes at single-implant restorations after local bone grafting in maxillas: a 3-year clinical prospective study case series. *Clin Implant Dent Relat Res* 2003;**5**:63–70.
39. Iizuka T, Smolka W, Hallermann W, Merckse-Stern R. Extensive augmentation of the alveolar ridge using autogenous calvarial split bone grafts for dental rehabilitation. *Clin Oral Implants Res* 2004;**15**:607–15.
40. Shiota T, Ohno K, Michi K, Tachikawa T. An experimental study of healing around hydroxylapatite implants installed with autogenous iliac bone grafts for jaw reconstruction. *J Oral Maxillofac Surg* 1991;**49**: 1310–5.
41. Rasmusson L, Meredith N, Kahnberg KE, Sennerby L. Effects of barrier membranes on bone resorption and implant stability in onlay bone grafts. An experimental study. *Clin Oral Implants Res* 1999;**4**:267–77.
42. Shanaman RH. A retrospective study of 237 sites treated consecutively with guided tissue regeneration. *Int J Periodontics Restor Dent* 1994;**14**:239–301.
43. Juodzbalys G, Raustia AM, Kubilius R. A 5-year follow-up study on one-stage implants inserted concomitantly with localized alveolar ridge augmentation. *J Oral Rehabil* 2007;**34**:781–9.
44. Buser D, Weber HP, Lang NP. Tissue integration of non-submerged implants. 1-Year results of a prospective study with 100 ITI hollow-cylinder and hollow-screw implants. *Clin Oral Implants Res* 1990;**1**:33–40.
45. Bragger U, Aeschlimann S, Burgin W, Hammerle CH, Lang NP. Biological and technical complications and failures with fixed partial dentures (FPD) on implants and teeth after four to five years of function. *Clin Oral Implants Res* 2001;**12**:26–34.
46. Albrektsson T, Isidor F. Consensus report of session IV. In: Lang NP, Karring T, editors. *Proceedings of the 1st European workshop on periodontology*. 1994:365–9.
47. Moher D, Liberati A, Tetzlaff J, Altman DG, The PRISMA Group. Preferred reporting items for systematic reviews and meta-analyses: the PRISMA statement. *Ital J Public Health* 2009;**6**:354–91.
48. Chiapasco M, Gatti C, Gatti F. Immediate loading of dental implants placed in severely resorbed edentulous mandibles reconstructed with autogenous calvarial grafts. *Clin Oral Implants Res* 2007;**18**:13–20.
49. Chiapasco M, Zaniboni M, Rimondini L. Autogenous onlay bone grafts vs. alveolar distraction osteogenesis for the correction of vertically deficient edentulous ridges: a 2–4-year prospective study on humans. *Clin Oral Implants Res* 2007;**18**:432–40.
50. Llambés F, Silvestre FJ, Caffesse R. Vertical guided bone regeneration with bioabsorbable barriers. *J Periodontol* 2007;**78**:2036–42.
51. Chiapasco M, Romeo E, Casentini P, Rimondini L. Alveolar distraction osteogenesis vs. vertical guided bone regeneration for the correction of vertically deficient edentulous ridges: a 1–3-year prospective study on humans. *Clin Oral Implants Res* 2004;**15**:82–95.
52. Buser D, Ingimarsson S, Dula K, Lussi A, Hirt HP, Belser UC. Long-term stability of osseointegrated implants in augmented

- bone: a 5-year prospective study in partially edentulous patients. *Int J Periodontics Restor Dent* 2002;**22**:109–17.
53. Brunel G, Brocard D, Duffort JF, Jacquet E, Justumus P, Simonet T, Benqué E. Bioabsorbable materials for guided bone regeneration prior to implant placement and 7-year follow-up: report of 14 cases. *J Periodontol* 2001;**72**:257–64.
54. Lorenzoni M, Pertl C, Polansky R, Wegscheider W. Guided bone regeneration with barrier membranes—a clinical and radiographic follow-up study after 24 months. *Clin Oral Implants Res* 1999;**10**:16–23.
55. Clementini M, Morlupi A, Canullo L, Agrestini C, Barlattani A. Success rate of dental implants inserted in horizontal and vertical guided bone regenerated areas: a systematic review. *Int J Oral Maxillofac Surg* 2012;**41**:847–52.
56. Chaytor DV, Zarb GA, Schmitt A, Lewis DW. The longitudinal effectiveness of osseointegrated dental implants. The Toronto study: bone level changes. *Int J Periodontics Restor Dent* 1991;**11**:1134–45.
57. Quirynen M, Naert I, van Steenberghe D, Nys L. A study of 589 consecutive implants supporting complete fixed prostheses. Part I: periodontal aspects. *J Prosthet Dent* 1992;**68**:655–63.
58. Lekholm U, van Steenberghe D, Herrmann I, Bolender C, Folmer T, Gunne J, Henry P, Higuchi K, Laney WR. Osseointegrated implants in the treatment of partially edentulous jaws: a prospective 5-year multicenter study. *Int J Oral Maxillofac Implants* 1994;**9**:627–35.
59. Behneke A, Behneke N, d'Hoedt T. The longitudinal clinical effectiveness of ITI solid screw implants in partially edentulous patients: a 5-year follow-up report. *Int J Oral Maxillofac Implants* 2000;**15**:633–45.

Address:  
 Marco Clementini  
 Policlinico Tor Vergata  
 Viale Oxford 81  
 00133 Rome  
 Italy  
 Tel: +39 338 8378866  
 E-mail: [mclementini@me.com](mailto:mclementini@me.com)