



# Fusion of ultrasound and 3D single-photon-emission computed tomography/computed tomography to identify sentinel lymph nodes in vulvar cancer: feasibility study

G. GARGANESE<sup>1,2</sup>, S. BOVE<sup>1,2</sup>, L. ZAGARIA<sup>3</sup>, F. MORO<sup>1</sup> , S. M. FRAGOMENI<sup>1</sup> , F. P. IERIA<sup>3</sup>, S. GENTILESCHI<sup>1</sup>, P. ROMEO<sup>4</sup>, D. DI GIORGIO<sup>2</sup>, A. GIORDANO<sup>3,5</sup>, G. SCAMBIA<sup>1,4</sup> and A. C. TESTA<sup>1,4</sup>

<sup>1</sup>Fondazione Policlinico Universitario Agostino Gemelli, IRCCS, Dipartimento Scienze della Salute della Donna, del Bambino e di Sanità Pubblica, Area Salute della Donna, Rome, Italy; <sup>2</sup>Mater Olbia Hospital, Gynecology and Breast Care Center, Olbia, Italy; <sup>3</sup>Fondazione Policlinico Universitario Agostino Gemelli, IRCCS, UOC Medicina Nucleare, Rome, Italy; <sup>4</sup>Università Cattolica del Sacro Cuore, Istituto di Clinica Ostetrica e Ginecologica, Rome, Italy; <sup>5</sup>Università Cattolica del Sacro Cuore, Istituto di Medicina Nucleare, Rome, Italy

**KEYWORDS:** fusion; sentinel lymph node; SPECT/CT; ultrasonography; vulvar cancer

## CONTRIBUTION

*What are the novel findings of this work?*

Previous studies have demonstrated the application of fusion imaging in oncology, but few data on this technique are available in gynecological oncology. We investigated the feasibility of fusion of ultrasound imaging and three-dimensional (3D) single-photon-emission computed tomography/computed tomography (SPECT/CT) in detecting sentinel lymph nodes in patients with vulvar cancer.

*What are the clinical implications of this work?*

Fusion of ultrasound and 3D SPECT/CT could improve the accuracy of SPECT/CT alone in preoperatively mapping sentinel lymph nodes. It could be used for ultrasound-guided sentinel lymph-node excision and, in intraoperative settings, to guide the surgeon in identifying target lymph nodes. Fusion imaging opens up new diagnostic and therapeutic opportunities in gynecological oncology.

## ABSTRACT

**Objective** To evaluate the feasibility of fusion of ultrasound imaging and three-dimensional (3D) single-photon-emission computed tomography/computed tomography (SPECT/CT) in detecting sentinel lymph nodes in women with vulvar cancer.

**Methods** This was a prospective pilot single-center study. Patients with vulvar cancer who were candidates for

sentinel lymph-node biopsy were enrolled between December 2018 and February 2019. Fusion imaging virtual navigation using 3D SPECT/CT and ultrasound was performed to investigate the tumor-draining lymph node. All clinical, imaging, surgical and histological information was collected prospectively and entered into a dedicated Excel file. Feasibility and success of fusion imaging virtual navigation and time needed to perform the three steps of fusion imaging were evaluated.

**Results** Ten lymph-node sites were evaluated in five consecutive women with a histological diagnosis of vulvar cancer. Fusion imaging virtual navigation was feasible and completed successfully for all (10/10) draining sites. Median overall time to perform fusion imaging was 32 (range, 25–40) min and the time decreased from the first to the last examination.

**Conclusions** The present study demonstrated that fusion imaging virtual navigation using 3D SPECT/CT and ultrasound is feasible and able to detect sentinel lymph nodes in women with vulvar carcinoma. Fusion imaging using ultrasound for detection of sentinel lymph nodes opens up multiple diagnostic and therapeutic opportunities in gynecological oncology. Copyright © 2019 ISUOG. Published by John Wiley & Sons Ltd.

## INTRODUCTION

Vulvar carcinoma is the fourth most common gynecological cancer, with an incidence of 1–3 per 100 000 women<sup>1–8</sup>. The initial spread usually occurs

Correspondence to: Dr F. Moro, Fondazione Policlinico Universitario Agostino Gemelli, IRCCS, Dipartimento Scienze della Salute della Donna, del Bambino e di Sanità Pubblica, Area Salute della Donna, L.go A. Gemelli 8, 00168 Rome, Italy (e-mail: morofrancy@gmail.com)

Accepted: 23 May 2019

to the inguinofemoral lymph nodes<sup>9</sup>, and lymph-node surgical staging is required in early-stage disease. Standard treatment of early-stage vulvar cancer consists of radical local excision of the tumor, sometimes with simultaneous plastic reconstruction<sup>10,11</sup>, combined with sentinel lymph-node biopsy and/or inguinofemoral lymphadenectomy<sup>12</sup>, according to the findings on preoperative lymph-node assessment. In particular, according to evidence reported recently in the literature, lymph-node negative status on imaging could be the most important criterion to indicate a sentinel lymph-node procedure, overcoming previous restrictive criteria and providing individualized risk assessment through advanced functional imaging tools<sup>13,14</sup>. Sentinel lymph-node biopsy is burdened by associated morbidity, while inguinofemoral lymphadenectomy is associated with significant short- and long-term complications such as wound breakdown, wound infection, lymphocele, lymphedema, cellulitis and erysipelas<sup>15–17</sup>. Therefore, accurate preoperative imaging to assess lymph-node status, as well as to identify and mark sentinel lymph nodes, is crucial to customize surgery and to avoid false-negative detection of sentinel lymph nodes. Currently, among imaging methods available for lymph-node status assessment (i.e. ultrasound, magnetic resonance imaging (MRI), computed tomography (CT) and positron emission tomography (PET)<sup>13,18–25</sup>), ultrasound examination has shown high sensitivity and specificity and is cost-effective, easy to learn and easy to perform<sup>18</sup>. Among diagnostic tools able to identify and map preoperatively a sentinel lymph node, single-photon-emission computed tomography (SPECT) has demonstrated a higher accuracy than has planar scintigraphy<sup>26–29</sup>.

In this context, fusion imaging virtual navigation is an advanced novel technology for precision imaging, which integrates real-time ultrasound images with cross-sectional images acquired previously using CT, MRI, SPECT/CT or PET/CT, exploiting all relevant functional and morphological information obtained by radiopharmaceuticals and contrast media<sup>30</sup>. Fusion imaging is currently recognized as a guide for diagnosis and for intervention of several pathologies. It represents the gold standard for diagnostic mapping biopsies and focal therapies in prostatic cancer<sup>31</sup>. It is validated for radiofrequency ablation in hepatocellular carcinoma<sup>32</sup> and for interventional percutaneous and endoscopic procedures for primary and metastatic abdominal lesions<sup>33,34</sup>. In particular, fusion imaging is useful when applied to the study of any disease that is poorly identifiable using ultrasound, but visible clearly with other imaging modalities. Fusion imaging has also been described recently in the detection of sentinel lymph nodes in patients with head and neck cancer<sup>35,36</sup>, as well as in those with breast cancer<sup>37,38</sup>.

However, the applications of fusion imaging in gynecological diseases are still poorly explored<sup>39–42</sup> and, to the best of our knowledge, no study has explored the role of fusion imaging in detecting sentinel lymph nodes in women with vulvar cancer. Thus, the present study aimed to evaluate the feasibility of fusion of three-dimensional

(3D) SPECT/CT and ultrasound imaging in detecting sentinel lymph nodes in women with vulvar cancer.

## METHODS

### Study design

This was a prospective pilot single-center study. This study was approved by the Institutional Review Board of the Department of Health Sciences of Women, Child and Public Health, Fondazione Policlinico Universitario A. Gemelli IRCCS (code 31-10-18/154). All enrolled women provided written informed consent. All data were collected in an electronic database and managed in accordance with privacy regulations. Between December 2018 and February 2019, all women with a histologically confirmed diagnosis of invasive vulvar cancer and who were candidates for sentinel lymph-node biopsy were evaluated for this study. After preoperative standard workup including <sup>18</sup>F-fluorodeoxyglucose-PET/CT and ultrasound examination for assessing inguinofemoral/pelvic lymph-node status, women with the following criteria were included: (1) indication for sentinel lymph-node biopsy; (2) underwent both lymphoscintigraphy and SPECT/CT examinations for detection of sentinel lymph nodes; (3) availability of a DICOM-format file of the 3D SPECT/CT volume; and (4) provided informed consent. The exclusion criterion was presence of a pacemaker implant.

Sentinel lymph-node biopsy was indicated according to both clinical examination and imaging, as described by the international guidelines, and after discussion in a dedicated weekly tumor board, supported by the vulvar cancer multidisciplinary team.

First, all enrolled patients underwent preoperative standard planar scintigraphy for sentinel lymph-node identification, using two-dimensional static imaging, and had a SPECT/CT examination to obtain a more precise 3D image of the tumor-draining lymph node. Second, fusion of 3D SPECT/CT and ultrasound imaging was performed to investigate the tumor-draining lymph node (virtual lymph node) and to mark it by introducing a metal clip (tissue marker). Finally, an intraoperative X-ray examination was performed to verify the correspondence between the virtual lymph node and the surgical lymph node identified by a standard radio-guided technique (gamma probe). Surgery was performed within 24 h after SPECT/CT examination and fusion of 3D SPECT/CT and ultrasound.

### Lymphoscintigraphy and intraoperative radio-guided localization

Between 4 and 24 h before surgery, and after local anesthesia with lidocaine spray, intradermal injection of <sup>99m</sup>Techetium-labeled albumin nanocolloids (Nanocoll®) was performed at four sites around the primary tumor<sup>43</sup>. A total activity of 37–148 MBq of radiocolloid, in four quantities of 0.2 mL, was administered. In case of multifocality or bilateralism, at

least two injection sites were allocated near each of the neoplastic foci. Dynamic images (Figure 1) were acquired immediately after the injection (15 min; 30 frames/s), followed by static planar imaging (time, 5 min; matrix,  $256 \times 256$ ; zoom, 1.33) in early phase (time, 15 min) and, if necessary, after a further 2 h (delayed phase). For every patient, after planar imaging, a tomographic image of the inguino-femoral and pelvic region was obtained using SPECT/CT<sup>44</sup>. The first lymph node(s) draining the vulva that appeared in the evaluated images was considered as sentinel lymph node(s). Under the guide of a gamma probe (Neoprobe 2000 or Neoprobe GDS; Mammotome, Rome, Italy), a skin tattoo identifying the sentinel lymph node was drawn preoperatively. Intraoperatively, the same probe guided the surgeon to localize and remove the sentinel lymph node<sup>45,46</sup>.

### SPECT/CT

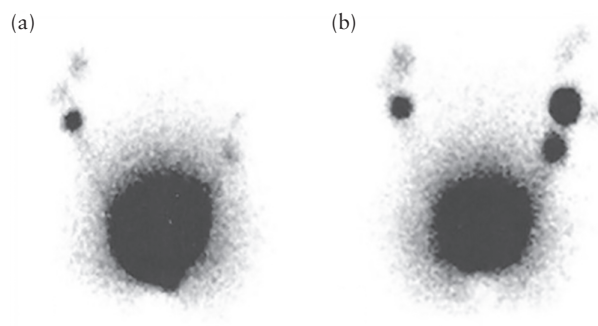
Using a dedicated twin-head hybrid camera (Symbia Intevo 2; Siemens Healthcare s.r.l., Milan, Italy), equipped with xSPECT™ technology, the SPECT images obtained from the inguino-femoral and pelvic region were fused with a coregistered CT scan to achieve localization and attenuation correction data. The acquisition settings for

xSPECT images consisted of: window, 140 keV (+20%); collimators, LEHR; matrix,  $256 \times 256$ ; zoom, 1.0; 128 views ( $2.8^\circ/\text{view}$ ); and step and shoot, 15 s/view. The acquisition settings for CT images, namely the low-dose technique, were: tube voltage, 130 keV, 30 mA; care dose type, AEC + DOM; pitch-factor, 1.2; slice, 3 mm. Reconstruction of SPECT/CT was performed using the ordered subset conjugate gradient minimizer method and all image files were saved in DICOM format<sup>47</sup> (Figure 2). The xSPECT technology allowed high-quality fused images to be obtained.

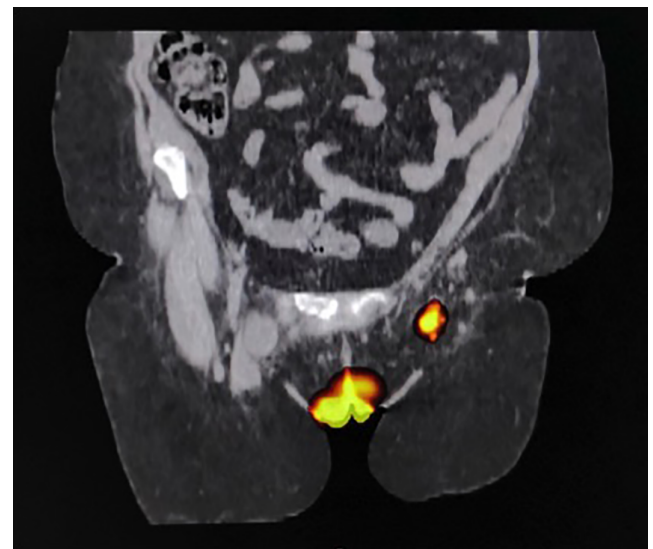
### Fusion imaging virtual navigation

First, a dedicated specialist in software learning gave a short training course to the ultrasound expert who had to learn how to use the fusion technique.


The fusion imaging system included the following components: a commercial ultrasound machine (MyLab™



**Figure 1** Planar lymphoscintigraphy in anterior view in woman with vulvar cancer, following early (after 15 min) (a) and delayed (after further 90–120 min) (b) image acquisition.



**Figure 2** Representative single-photon-emission computed tomography/computed tomography image, obtained using xSPECT™ method, in woman with vulvar cancer, showing sentinel lymph node in left groin.



**Figure 3** Fusion imaging virtual navigation system. (a) Ultrasound machine with integrated navigation software. (b) Magnetic field generator. (c) Ultrasound probe, with sensor attached to probe handle, and transmitter.

Eight eXP; Esaote S.p.A., Genoa, Italy) combined with virtual navigation software (Esaote) integrated with an electromagnetic tracking system able to record the position and orientation of the probe in a 3D environment. The electromagnetic tracking system consisted of: a magnetic field generator placed near the patient and the region of interest, generating a magnetic ampoule of about 80 cm; a sensor attached to the handle of the ultrasound probe, able to detect 3D spatial information; and a transmitter which tracks the probe's spatial position (Figure 3).

The whole procedure included the following three steps (Videoclip S1): the first step was acquisition of 3D volumes and target identification on CT and SPECT. The standard DICOM/JPEG images from SPECT and CT 3D volumes were loaded on the software, the CT and SPECT cross-sectional images were compared on the screen, synchronized and jointly scrolled, showing the multimodal images on the same scan. After identification of the target sentinel lymph node(s) on both CT and SPECT images, a colored marker (virtual marker) was set; multiple colored markers could be placed for multiple targets. The second step was coregistration and synchronization of 3D SPECT/CT and ultrasound images. The transmitter tracked on SPECT/CT the movements of the sensor on the ultrasound handle. Any precise anatomical structure that could be recognized on both examinations was frozen and taken as a primary landmark(s); generally, the primary landmark for the pelvic region was the pubic symphysis. This step allowed the alignment of SPECT/CT and ultrasound images. Once primary landmarks were identified on both images (ultrasound and SPECT/CT), the dynamic navigation was generated. The third step was fine tuning and fusion imaging navigation. During fusion imaging navigation, small misalignments could be corrected by freezing the SPECT/CT image and realigning it with the ultrasound scan. This process could be accomplished by minute fine-tuning movements performed using additional anatomical reference points (secondary landmarks).

The most frequent primary landmarks used in this study were the pubic symphysis, saphenofemoral junction, femoral bifurcation and iliac bifurcation. The most common secondary landmarks were vascular ramifications, close lymph nodes, muscular structures and bone structures. Fusion navigation was completed when the virtual marker, indicating the sentinel lymph node that was previously fixed on SPECT/CT images, was clearly identified on the ultrasound screen.

### Presurgical, surgical and histopathological procedures

At the end of fusion navigation, a tissue marker was placed to locate the sentinel lymph node. The tissue marker was a 5-mm amagnetic metallic clip (MammoMARK™; Devicor Medical Products Inc., part of Lecia Biosystems, Cincinnati, OH, USA). All women were questioned about their allergy history and, after skin disinfection and local anesthesia with lidocaine or mepivacaine, the tissue marker was introduced into the lymph node by means of

a specific introducer under 3D SPECT/CT and ultrasound fusion guidance.

Dedicated gynecological oncology surgeons performed all surgical procedures. Intraoperative lymphatic mapping was performed using the double combined standard technique (vulvar subdermal injection of blue dye and radiocolloid). An intraoperative X-ray examination of the surgical sentinel lymph node was performed to verify the presence of the tissue marker. The correspondence between the virtual and surgical sentinel lymph nodes was considered the standard of reference to evaluate the success of fusion imaging virtual navigation.

The removed sentinel lymph nodes underwent a pathological ultrastaging examination. The sentinel lymph-node serial sections were 5-mm thick and were analyzed using routine hematoxylin and eosin staining<sup>48–52</sup>. If indicated, radical inguino-femoral lymphadenectomy was performed according to guidelines, sparing the main neurovascular structures (great saphenous vein and tributary vessels as inferior superficial epigastric, external pudendal and superficial iliac circumflex vessels) whenever possible.

### Statistical analysis

All clinical, imaging, surgical and histological information was collected prospectively and entered into a dedicated Excel file. Data were expressed as median (range) or *n* (%), as appropriate. Stata software version 13.0 (Stata Corp, College Station, TX, USA) was used for data analyses.

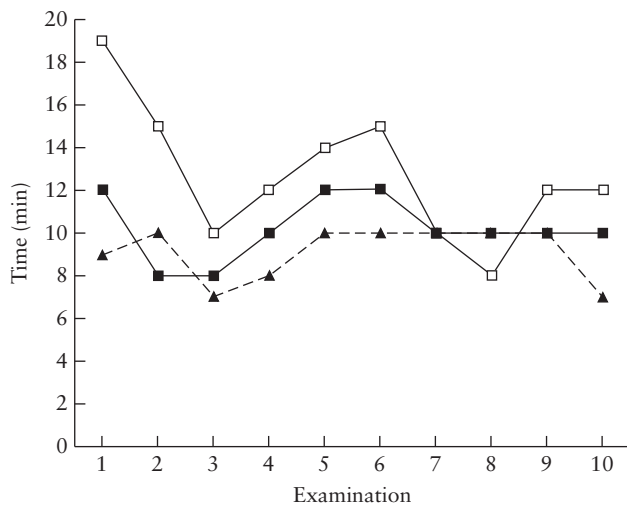
Feasibility, success of fusion imaging virtual navigation (as determined by the capacity of the technique to identify the sentinel lymph node) and time needed to perform each of the three steps of fusion imaging were evaluated.

## RESULTS

Between December 2018 and February 2019, five consecutive patients with a histological diagnosis of vulvar cancer, who were candidates for sentinel lymph-node biopsy and had undergone preoperative lymphoscintigraphy and 3D SPECT/CT, were selected. Ten lymph-node sites were evaluated using fusion imaging virtual navigation. Median age at diagnosis was 59 (range, 56–83) years and median body mass index (BMI) was 34 (range, 23–39) kg/m<sup>2</sup>. Three of five (60%) patients had BMI > 30 kg/m<sup>2</sup> and all but one had a comorbidity (i.e. diabetes or cardiovascular pathology).

3D SPECT/CT was performed successfully in all patients and the sentinel lymph nodes were identified in all (10/10) draining sites. The vulvar sentinel lymph nodes were bilateral in all cases.

Fusion imaging virtual navigation was completed successfully for all (10/10) draining sites and the virtual marker was found in all lymph-node sites. The tissue marker was always placed correctly in the virtual sentinel lymph nodes using fusion examination. Intraoperatively, the sentinel lymph nodes were recognized in all cases



**Figure 4** Duration of three steps of ultrasound and three-dimensional (3D) single-photon-emission computed tomography/computed tomography (SPECT/CT) fusion imaging for detection of sentinel lymph nodes in 10 examinations performed by same operator in five women with vulvar cancer. Step 1 (—■—) is acquisition of 3D volumes and target identification on SPECT and CT. Step 2 (---▲---) is coregistration and synchronization of SPECT/CT and ultrasound images. Step 3 (---□---) is fine tuning and fusion imaging navigation.

by the gamma probe and surgically removed. X-ray examination confirmed the presence of the tissue marker inside the surgical specimen in 10/10 cases, confirming the feasibility of the fusion technique.

Median overall time to perform fusion imaging was 32 (range, 25–40) min. Median duration of Step 1 (acquisition of 3D volumes and target identification on CT and SPECT) was 10 (range, 8–12) min; of Step 2 (coregistration and synchronization of SPECT/CT and ultrasound) was 10 (range, 7–10) min; and of Step 3 (fine tuning and SPECT/CT and ultrasound fusion imaging navigation) was 12 (range, 8–19) min. Time spent performing Steps 1 and 2 was similar in all 10 cases, whereas the time spent performing Step 3 reduced significantly from the first to the last examination (19 vs 12 min; Figure 4).

## DISCUSSION

The present study demonstrated that fusion imaging virtual navigation using 3D SPECT/CT and ultrasound is feasible and able to detect sentinel lymph nodes in women with vulvar carcinoma. Median overall time to perform fusion imaging was 32 (range, 25–40) min and decreased from the first to the last examination.

To the best of our knowledge, this is the first study exploring the use of fusion imaging combining ultrasound with SPECT/CT for examination of sentinel lymph nodes in gynecological oncology. SPECT/CT and ultrasound were included in the routine preoperative workup of patients with vulvar cancer who were candidates for sentinel lymph-node biopsy. The main limitation of this study is the small sample size, even though it is consistent with that of previous studies. Indeed, the vast majority of studies reporting the feasibility of fusion

imaging in gynecological diseases included only a few cases. This could be explained by the fact that fusion imaging using ultrasound is an innovative technique and its possible applications in gynecology are still being explored. Millischer *et al.*<sup>40</sup> were the first to describe the role of fusion imaging in gynecology. They demonstrated in a prospective study involving 17 patients that, by combining the information from both ultrasound and MRI, the performance of these imaging modalities alone in the identification of the main anatomical sites of deep infiltrating endometriosis could be improved. Three studies have since been conducted on ultrasound fusion imaging in gynecology<sup>39,41,42</sup>, only one of which explored its use in gynecological oncology<sup>39</sup>. Théodore *et al.*<sup>39</sup> showed, in 13 patients with cervical cancer, that MRI and ultrasound fusion imaging could improve cervical cancer lesion characterization and parametrial infiltration detection in comparison with MRI alone.

Fusion techniques using ultrasound for sentinel lymph-node detection have been assessed by other authors, but in different settings; namely, in patients with head and neck cancer<sup>35,36</sup>, and in those with breast cancer<sup>37,38</sup>.

Other authors focused on the role of fusion imaging without integrated ultrasound in detecting a targeted lymph node in gynecological oncology<sup>51–53</sup>. In a retrospective study involving 27 cases with endometrial or cervical cancer, Stecco *et al.*<sup>51</sup> demonstrated a greater accuracy of fusion imaging using PET and MRI diffusion-weighted imaging (DWI) in detecting a metastatic lymph node than that of PET/CT or MRI-DWI alone. Kraft and Havel<sup>52</sup> showed that fusion imaging using SPECT and CT improved the detection of a sentinel lymph node when compared to planar lymphoscintigraphy in a series of 64 patients with gynecological cancer (36 with cervical, 21 with endometrial and seven with vulvar cancer). In a series of 10 patients with vulvar cancer, Beneder *et al.*<sup>53</sup> demonstrated that fusion imaging using SPECT and CT/MRI was feasible and detected sentinel lymph nodes more precisely than did planar imaging in terms of number and anatomical location.

Our series of women with vulvar cancer, who were candidates for sentinel lymph-node surgery and examined using 3D SPECT/CT and ultrasound fusion imaging, was limited. However, this series was sufficient to understand the possible future applications of fusion imaging in this setting. In particular, fusion of SPECT/CT and ultrasound images could improve the accuracy of SPECT/CT alone in preoperatively mapping sentinel lymph nodes, and this is worth exploring. Fusion imaging could also be used for ultrasound-guided sentinel lymph-node biopsy or excision. Moreover, fusion technique could be useful in intraoperative settings to guide the surgeon in identifying precisely target lymph nodes; indeed, in patients with inferior-limb lymphedema, the surgeon may need guidance to find the last draining lymph node for performing lymphatic-venous anastomosis.

As this study has demonstrated fusion imaging to be feasible, it can now be applied to a larger sample size

of patients with vulvar cancer; other imaging methods, such as PET/CT, CT or MRI instead of SPECT/CT, could be considered in the location of superficial lymph nodes, for instance, which may be unrecognizable on ultrasound examination alone.

It is worth noting that fusion of two techniques, such as SPECT/CT and ultrasound, allows close collaboration between radiologists, nuclear medicine physicians and oncological gynecologists. This cooperation could increase not only the diagnostic accuracy of single imaging methods, but also the expertise of the specialists.

We also found that the time spent performing fusion imaging virtual navigation decreased from the first to the last examination. This suggests that the time depends on operator experience in performing fusion imaging, even if they are a dedicated gynecologist in the diagnosis and treatment of vulvar cancer. Further prospective studies should be conducted to assess the learning curve of non-expert radiologists and gynecologists to perform fusion imaging, and to investigate new applications of the technique in gynecological oncology.

In conclusion, this study demonstrated that fusion imaging virtual navigation using 3D SPECT/CT and ultrasound is feasible and able to detect sentinel lymph nodes in women with vulvar carcinoma. Fusion imaging using ultrasound to detect sentinel lymph nodes opens up multiple diagnostic and therapeutic opportunities in gynecological oncology.

## REFERENCES

- Howlander N, Noone AM, Krapcho M, Miller D, Bishop K, Kosary CL, Yu M, Ruhl J, Tatalovich Z, Mariotto A, Lewis DR, Chen HS, Feuer EJ, Cronin KA (eds). SEER Cancer Statistics Review, 1975–2014, National Cancer Institute, Bethesda, MD, [https://seer.cancer.gov/archive/csr/1975\\_2014/](https://seer.cancer.gov/archive/csr/1975_2014/), based on November 2016 SEER data submission, posted to the SEER website, April 2007.
- National Cancer Intelligence Network (NCIN). Vulvar Cancer – Trends and Variations by Age, May 2014. [http://www.ncin.org.uk/cancer\\_type\\_and\\_topic\\_specific\\_work/cancer\\_type\\_specific\\_work/gynaecological\\_cancer/gynaecological\\_cancer\\_hub/resources/vulval\\_and\\_vagina\\_cancer](http://www.ncin.org.uk/cancer_type_and_topic_specific_work/cancer_type_specific_work/gynaecological_cancer/gynaecological_cancer_hub/resources/vulval_and_vagina_cancer)
- Schuurman MS, van den Einden LCG, Massuger LF a. G, Kiemeneij LA, van der Aa MA, de Hullu JA. Trends in incidence and survival of Dutch women with vulvar squamous cell carcinoma. *Eur J Cancer* 2013; **49**: 3872–3880.
- Hampel M, Deckers-Figiel S, Hampel JA, Rein D, Bender HG. New aspects of vulvar cancer: changes in localization and age of onset. *Gynecol Oncol* 2008; **109**: 340–345.
- Sankaranarayanan R, Ferlay J. Worldwide burden of gynaecological cancer: the size of the problem. *Best Pract Res Clin Obstet Gynaecol* 2006; **20**: 207–225.
- Saraiya M, Watson M, Wu X, King JB, Chen VW, Smith JS, Giuliano AR. Incidence of *in situ* and invasive vulvar cancer in the US, 1998–2003. *Cancer* 2008; **113**: 2865–2872.
- Tagliaferri L, Casà C, Macchia G, Pesce A, Garganese G, Gui B, Perotti G, Gentileschi S, Inzani F, Autorino R, Cammelli S, Morganti AG, Valentini V, Gambacorta MA. The Role of Radiotherapy in Extramammary Paget Disease: A Systematic Review. *Int J Gynecol Cancer* 2018; **28**: 829–839.
- Mantovani G, Fagotti A, Franchi M, Scambia G, Garganese G. Reviewing vulvar Paget's disease molecular bases. Looking forward to personalized target therapies: a matter of CHANGE. *Int J Gynecol Cancer* 2019; **29**: 422–429.
- Pouwer A-FW, Arts HJ, van der Velden J, de Hullu JA. Limiting the morbidity of inguofemoral lymphadenectomy in vulvar cancer patients; a review. *Expert Rev Anticancer Ther* 2017; **17**: 615–624.
- Gentileschi S, Servillo M, Garganese G, Fragomeni S, De Bonis F, Scambia G, Salgarello M. Surgical therapy of vulvar cancer: how to choose the correct reconstruction? *J Gynecol Oncol* 2016; **27**: e60.
- Gentileschi S, Servillo M, Garganese G, Simona F, Scambia G, Salgarello M. Versatility of pedicled anterolateral thigh flap in gynecologic reconstruction after vulvar cancer extirpative surgery. *Microsurgery* 2017; **37**: 516–524.
- Van der Zee AGJ, Oonk MH, De Hullu JA, Ansink AC, Vergote I, Verheijen RH, Maggioni A, Gaarenstroom KN, Baldwin PJ, Van Dorst EB, Van der Velden J, Hermans RH, van der Putten H, Drouin P, Schneider A, Sluiter WJ. Sentinel node dissection is safe in the treatment of early-stage vulvar cancer. *J Clin Oncol* 2008; **26**: 884–889.
- Garganese G, Collarino A, Fragomeni SM, Rufini V, Perotti G, Gentileschi S, Evangelista MT, Ieria FP, Zagaria L, Bove S, Giordano A, Scambia G. Groin sentinel node biopsy and 18F-FDG PET/CT-supported preoperative lymph node assessment in cN0 patients with vulvar cancer currently unfit for minimally invasive inguinal surgery: The GroSNaPET study. *Eur J Surg Oncol* 2017; **43**: 1776–1783.
- Collarino A, Garganese G, Fragomeni SM, Pereira Arias-Bouda LM, Ieria FP, Boellaard R, Rufini V, de Geus-Oei LF, Scambia G, Valdés Olmos RA, Giordano A, Grootjans W, van Velden FHP. Radiomics in vulvar cancer: first clinical experience using 18F-FDG PET/CT images. *J Nucl Med* 2019; **60**: 199–206.
- Gaarenstroom KN, Kenter GG, Trimbos JB, Agous I, Amant F, Peters AA, Vergote I. Postoperative complications after vulvectomy and inguofemoral lymphadenectomy using separate groin incisions. *Int J Gynecol Cancer* 2003; **13**: 522–527.
- Fanfani F, Garganese G, Fagotti A, Lorusso D, Gagliardi ML, Rossi M, Salgarello M, Scambia G. Advanced vulvar carcinoma: is it worth operating? A perioperative management protocol for radical and reconstructive surgery. *Gynecol Oncol* 2006; **103**: 467–472.
- Gentileschi S, Servillo M, Garganese G, Fragomeni S, De Bonis F, Cina A, Scambia G, Salgarello M. The lymphatic superficial circumflex iliac vessels deep branch perforator flap: A new preventive approach to lower limb lymphedema after groin dissection-preliminary evidence. *Microsurgery* 2017; **37**: 564–573.
- de Gregorio N, Ebner F, Schwentner L, Friedl TWP, Deniz M, Látó K, Kreenberg R, Janni W, Varga D. The role of preoperative ultrasound evaluation of inguinal lymph nodes in patients with vulvar malignancy. *Gynecol Oncol* 2013; **131**: 113–117.
- Hall TB, Barton DPJ, Trott PA, Nasiri N, Shepherd JH, Thomas JM, Moskvic EC. The role of ultrasound-guided cytology of groin lymph nodes in the management of squamous cell carcinoma of the vulva: 5-year experience in 44 patients. *Clin Radiol* 2003; **58**: 367–371.
- Land R, Herod J, Moskvic E, King M, Sohaib SA, Trott P, Nasiri N, Shepherd JH, Bridges JE, Ind TE, Blake P, Barton DP. Routine computerized tomography scanning, groin ultrasound with or without fine needle aspiration cytology in the surgical management of primary squamous cell carcinoma of the vulva. *Int J Gynecol Cancer* 2006; **16**: 312–317.
- Lin G, Chen CY, Liu FY, Yang LY, Huang HJ, Huang YT, Jung SM, Chou HH, Lai CH, Ng KK. Computed tomography, magnetic resonance imaging and FDG positron emission tomography in the management of vulvar malignancies. *Eur Radiol* 2015; **25**: 1267–1278.
- Cohn DE, Dehdashti F, Gibb RK, Mutch DG, Rader JS, Siegel BA, Herzog TJ. Prospective evaluation of positron emission tomography for the detection of groin node metastases from vulvar cancer. *Gynecol Oncol* 2002; **85**: 179–184.
- Kamran MW, O'Toole F, Meghen K, Wahab AN, Saadeh FA, Gleeson N. Whole-body [18F]fluoro-2-deoxyglucose positron emission tomography scan as combined PET-CT staging prior to planned radical vulvectomy and inguofemoral lymphadenectomy for squamous vulvar cancer: a correlation with groin node metastasis. *Eur J Gynaecol Oncol* 2014; **35**: 230–235.
- Dolanbay M, Ozcelik B, Abdulrezzak U, Serin IS, Kutuk MS, Uludag S. F-18 fluoro-D-glucose (FDG)-positron emission tomography (PET)/computed tomography (CT) in planning of surgery and sentinel lymph node screening in vulvar cancers. *Arch Gynecol Obstet* 2016; **293**: 1319–1324.
- Collarino A, Garganese G, Valdés Olmos RA, Stefanelli A, Perotti G, Mirk P, Fragomeni SM, Ieria FP, Scambia G, Giordano A, Rufini V. Evaluation of Dual-Timepoint 18F-FDG PET/CT Imaging for Lymph Node Staging in Vulvar Cancer. *J Nucl Med* 2017; **58**: 1913–198.
- Klapdor R, Länger F, Gratz KF, Hillemanns P, Hertel H. SPECT/CT for SLN dissection in vulvar cancer: Improved SLN detection and dissection by preoperative three-dimensional anatomical localisation. *Gynecol Oncol* 2015; **138**: 590–596.
- Lerman H, Lievshitz G, Zak O, Metser U, Schneebaum S, Even-Sapir E. Improved sentinel node identification by SPECT/CT in overweight patients with breast cancer. *J Nucl Med* 2007; **48**: 201–206.
- Vermeeren L, van der Ploeg IMC, Olmos RAV, Meinhardt W, Klop WMC, Kroon BB, Nieweg OE. SPECT/CT for preoperative sentinel node localization. *J Surg Oncol* 2010; **101**: 184–190.
- Keidar Z, Israel O, Krausz Y. SPECT/CT in tumor imaging: technical aspects and clinical applications. *Semin Nucl Med* 2003; **33**: 205–218.
- Jung EM, Friedrich C, Hoffstetter P, Dendl LM, Klebl F, Agha A, Wiggermann P, Stroszcynski C, Schreyer AG. Volume navigation with contrast enhanced ultrasound and image fusion for percutaneous interventions: first results. *PLoS One* 2012; **7**: e33956.
- Miyagawa T, Ishikawa S, Kimura T, Suetomi T, Tsutsumi M, Irie T, Kondoh M, Mitake T. Real-time Virtual Sonography for navigation during targeted prostate biopsy using magnetic resonance imaging data. *Int J Urol* 2010; **17**: 855–860.
- Liu F-Y, Yu X-L, Liang P, Cheng Z-G, Han Z-Y, Dong B-W, Zhang XH. Microwave ablation assisted by a real-time virtual navigation system for hepatocellular carcinoma undetectable by conventional ultrasonography. *Eur J Radiol* 2012; **81**: 1455–1459.
- Haber G-P, Colombo JR, Remer E, O'Malley C, Ukimura O, Magi-Galluzzi C, Spaliviero M, Kaouk J. Synchronized real-time ultrasonography and three-dimensional computed tomography scan navigation during percutaneous renal cryoablation in a porcine model. *J Endourol* 2010; **24**: 333–337.
- Hamamoto S, Unno R, Taguchi K, Ando R, Hamakawa T, Naiki T, Okada S, Inoue T, Okada A, Kohri K, Yasui T. A New Navigation System of Renal Puncture for Endoscopic Combined Intrarenal Surgery: Real-time Virtual Sonography-guided Renal Access. *Urology* 2017; **109**: 44–50.
- de Bree R, Pouw B, Heuveling DA, Castelijns JA. Fusion of Freehand SPECT and Ultrasound to Perform Ultrasound-Guided Fine-Needle Aspiration Cytology of Sentinel Nodes in Head and Neck Cancer. *AJNR Am J Neuroradiol* 2015; **36**: 2153–2158.
- Bluemel C, Safak G, Cramer A, Wöckel A, Gesierich A, Hartmann E, Schmid JS, Kaiser F, Buck AK, Herrmann K. Fusion of freehand SPECT and ultrasound: First experience in preoperative localization of sentinel lymph nodes. *Eur J Nucl Med Mol Imaging* 2016; **43**: 2304–2312.

37. Okur A, Hennesperger C, Runyan B, Gardiazaball J, Keicher M, Paepke S, Wendler T, Navab N. FhSPECT-US guided needle biopsy of sentinel lymph nodes in the axilla: is it feasible? *Med Image Comput Assist Interv* 2014; **17**: 577–584.
38. Freesmeyer M, Winkens T, Opfermann T, Elsner P, Runnebaum I, Darr A. Real-time ultrasound and freehand-SPECT. Experiences with sentinel lymph node mapping. *Nuklearmedizin* 2014; **53**: 259–264.
39. Théodore C, Levaillant JM, Capmas P, Chabi N, Skalli D, Vienet-Leguë L, Haddad B, Fernandez H, Touboul C. MRI and Ultrasound Fusion Imaging for Cervical Cancer. *Anticancer Res* 2017; **37**: 5079–5085.
40. Millischer A-E, Salomon LJ, Santulli P, Borghese B, Dousset B, Chapron C. Fusion imaging for evaluation of deep infiltrating endometriosis: feasibility and preliminary results. *Ultrasound Obstet Gynecol* 2015; **46**: 109–117.
41. Vinci V, Saldari M, Sergi ME, Bernardo S, Rizzo G, Porpora MG, Catalano C, Manganaro L. MRI, US or real-time virtual sonography in the evaluation of adenomyosis? *Radiol Med* 2017; **122**: 361–368.
42. Berger J, Henneman O, Rhemrev J, Smeets M, Jansen FW. MRI-Ultrasound Fusion Imaging for Diagnosis of Deep Infiltrating Endometriosis - A Critical Appraisal. *Ultrasound Int Open* 2018; **4**: E85–90.
43. Giammarile F, Bozkurt MF, Cibula D, Pahisa J, Oyen WJ, Paredes P, Olmos RV, Sicart SV. The EANM clinical and technical guidelines for lymphoscintigraphy and sentinel node localization in gynaecological cancers. *Eur J Nucl Med Mol Imaging* 2014; **41**: 1463–1477.
44. Valdés Olmos RA, Rietbergen DD, Vidal-Sicart S, Manca G, Giammarile F, Mariani G. Contribution of SPECT/CT imaging to radioguided sentinel lymph node biopsy in breast cancer, melanoma, and other solid cancers: from “open and see” to “see and open.” *Q J Nucl Med Mol Imaging* 2014; **58**: 127–139.
45. Meads C, Sutton AJ, Rosenthal AN, Malysiak S, Kowalska M, Zapalska A, Rogozińska E, Baldwin P, Ganesan R, Borowiack E, Barton P, Roberts T, Khan K, Sundar S. Sentinel lymph node biopsy in vulvar cancer: systematic review and meta-analysis. *Br J Cancer* 2014; **110**: 2837–2846.
46. Sliutz G, Reinthaller A, Lantzsch T, Mende T, Sinzinger H, Kainz C, Koelbl H. Lymphatic mapping of sentinel nodes in early vulvar cancer. *Gynecol Oncol* 2002; **84**: 449–452.
47. Hans Vija, PhD, Siemens Medical Solutions, Inc. Introduction to xSPECT Technology: Evolving Multi-modal SPECT to Become Context-based and Quantitative. [https://static.healthcare.siemens.com/siemens\\_hwem-hwem\\_sxxa\\_websites-context-root/wcm/id/groups/public/@global/@imaging/@molecular/documents/download/mdax/otiz/-edisp/final\\_new\\_xspect\\_wp.2-00960488.pdf](https://static.healthcare.siemens.com/siemens_hwem-hwem_sxxa_websites-context-root/wcm/id/groups/public/@global/@imaging/@molecular/documents/download/mdax/otiz/-edisp/final_new_xspect_wp.2-00960488.pdf)
48. Morton DL, Wen DR, Wong JH, Economou JS, Cagle LA, Storm FK, Foshag LJ, Cochran AJ. Technical details of intraoperative lymphatic mapping for early stage melanoma. *Arch Surg* 1992; **127**: 392–399.
49. Levenback C, Burke TW, Gershenson DM, Morris M, Malpica A, Ross MI. Intraoperative lymphatic mapping for vulvar cancer. *Obstet Gynecol* 1994; **84**: 163–167.
50. De Hullu JA, Oonk MHM, Ansink AC, Hollema H, Jager PL, van der Zee AGJ. Pitfalls in the sentinel lymph node procedure in vulvar cancer. *Gynecol Oncol* 2004; **94**: 10–15.
51. Stecco A, Buemi F, Cassarà A, Matheoud R, Sacchetti GM, Arnulfo A, Brambilla M, Carriero A. Comparison of retrospective PET and MRI-DWI (PET/MRI-DWI) image fusion with PET/CT and MRI-DWI in detection of cervical and endometrial cancer lymph node metastases. *Radiol Med* 2016; **121**: 537–545.
52. Kraft O, Havel M. Detection of Sentinel Lymph Nodes in Gynecologic Tumours by Planar Scintigraphy and SPECT/CT. *Mol Imaging Radionucl Ther* 2012; **21**: 47–55.
53. Bener C, Fuechsel FG, Krause T, Kuhn A, Mueller MD. The role of 3D fusion imaging in sentinel lymphadenectomy for vulvar cancer. *Gynecol Oncol* 2008; **109**: 76–80.

## SUPPORTING INFORMATION ON THE INTERNET

The following supporting information may be found in the online version of this article:



**Videoclip S1** Three steps of ultrasound and 3D single-photon-emission computed tomography/computed tomography (SPECT/CT) fusion imaging technique.