



## Novel clinical features associated with Clouston syndrome

Cammarata-Scalisi, F., Rinelli, M., Pisaneschi, E., Diociaiuti, A., Willoughby, C. E., Avendaño, A., Digilio, M. C., Novelli, A., & Callea, M. (2019). Novel clinical features associated with Clouston syndrome. *International Journal of Dermatology*, 58(8), e143-e146. <https://doi.org/10.1111/ijd.14507>

[Link to publication record in Ulster University Research Portal](#)

**Published in:**

International Journal of Dermatology

**Publication Status:**

Published (in print/issue): 01/08/2019

**DOI:**

[10.1111/ijd.14507](https://doi.org/10.1111/ijd.14507)

**Document Version**

Publisher's PDF, also known as Version of record

**Document Licence:**

Unspecified

**General rights**

The copyright and moral rights to the output are retained by the output author(s), unless otherwise stated by the document licence.

Unless otherwise stated, users are permitted to download a copy of the output for personal study or non-commercial research and are permitted to freely distribute the URL of the output. They are not permitted to alter, reproduce, distribute or make any commercial use of the output without obtaining the permission of the author(s).

If the document is licenced under Creative Commons, the rights of users of the documents can be found at <https://creativecommons.org/share-your-work/licenses/>.

**Take down policy**

The Research Portal is Ulster University's institutional repository that provides access to Ulster's research outputs. Every effort has been made to ensure that content in the Research Portal does not infringe any person's rights, or applicable UK laws. If you discover content in the Research Portal that you believe breaches copyright or violates any law, please contact [pure-support@ulster.ac.uk](mailto:pure-support@ulster.ac.uk)

## Correspondence

### Novel clinical features associated with Clouston syndrome

Clouston syndrome (OMIM #129500), also known as hidrotic ectodermal dysplasia type 2, is a rare autosomal dominant ectodermal dysplasia.<sup>1–4</sup> It is characterized by a triad of major features that include partial to complete hair loss, severe nail dystrophy, and palmoplantar hyperkeratosis with varying degrees of severity.<sup>1–6</sup> In affected individuals, the hair is pale, fine, sparse, and grows very slowly, and total alopecia may occur. The eyebrows and eyelashes are absent or sparse and short. Nail abnormalities are characterized by thickened, ridged, hyperconvex nails, and paronychia is frequently reported.<sup>3</sup> The teeth, sweat, and sebaceous glands are normal.<sup>1,2</sup> Additional clinical features include sensorineural deafness,<sup>5–7</sup> hyperpigmentation of the skin over large joints,<sup>3,6</sup> and eccrine syringofibroadenoma (Table 1).<sup>8</sup>

Heterozygous mutations in the gap junction beta 6 gene, (*GJB6*, OMIM #604418), which encodes the gap junction protein connexin 30 (Cx30), result in Clouston syndrome.<sup>1,3</sup> Four heterozygous missense mutations (G11R, V37E, D50N, and A88V) account for the majority of Clouston syndrome cases.<sup>1–3</sup> Herein, we describe a Venezuelan child who presented with a mild phenotype resulting from an A88V mutation, in *GJB6*, who demonstrates novel clinical features associated with Clouston syndrome expanding the phenotypic spectrum.

The patient was a 4-year-old Venezuelan boy, born from non-consanguineous healthy parents (III:2), and the only affected

individual in the family (Fig. 1a). Dermatologic examination at his first evaluation detected hair loss in the temporo-occipital area (Fig. 1b) with sparse, pale, brittle hair on the scalp, abnormalities of the eyebrows and eyelashes (Fig. 1c), and slight hypertrichosis on the posterior thorax (Fig. 1d). His fingernails and toenails were dystrophic, short, whitened, and thickened with distal wedge-shaped separation, associated with mild paronychia (Fig. 1e,f). He had palmar hyperhidrosis without palmoplantar keratoderma (Fig. 1g). There was hyperpigmentation in the periorbital region (Fig. 1c) and over the elbows and knees. Sweating and teeth were normal. Ophthalmic examination at 9 years of age detected myopia and astigmatism. Audiologic testing revealed mild sensorineural hearing loss.

Targeted next generation sequencing detected a heterozygous mutation c.263C>T (rs28937872) in the *GJB6* gene (NM\_001110221.2) resulting in A88V (NP\_001103691.1) non-synonymous mutation (Fig. 2a). The mutation was confirmed by Sanger sequencing in the proband, and sequencing of both parents and the brother confirmed absence of this sequence variant, and hence this mutation arose *de novo* (Fig. 2b). A number of bioinformatics modeling tools were employed to determine the pathogenicity of the A88V mutation and to predict the possible impact on the structure or function of Cx30 protein. Polyphen2<sup>9</sup> predicted the mutation as damaging (with a score of 0.984), and MutationTaster<sup>10</sup> classified this variant as a disease-causing mutation. The conservation of the wild-type nucleotide was assessed using PhastCons and PhyloP, and

**Table 1** Clinical features of reported Clouston syndrome cases resulting from the A88V mutation in literature *GJB6*

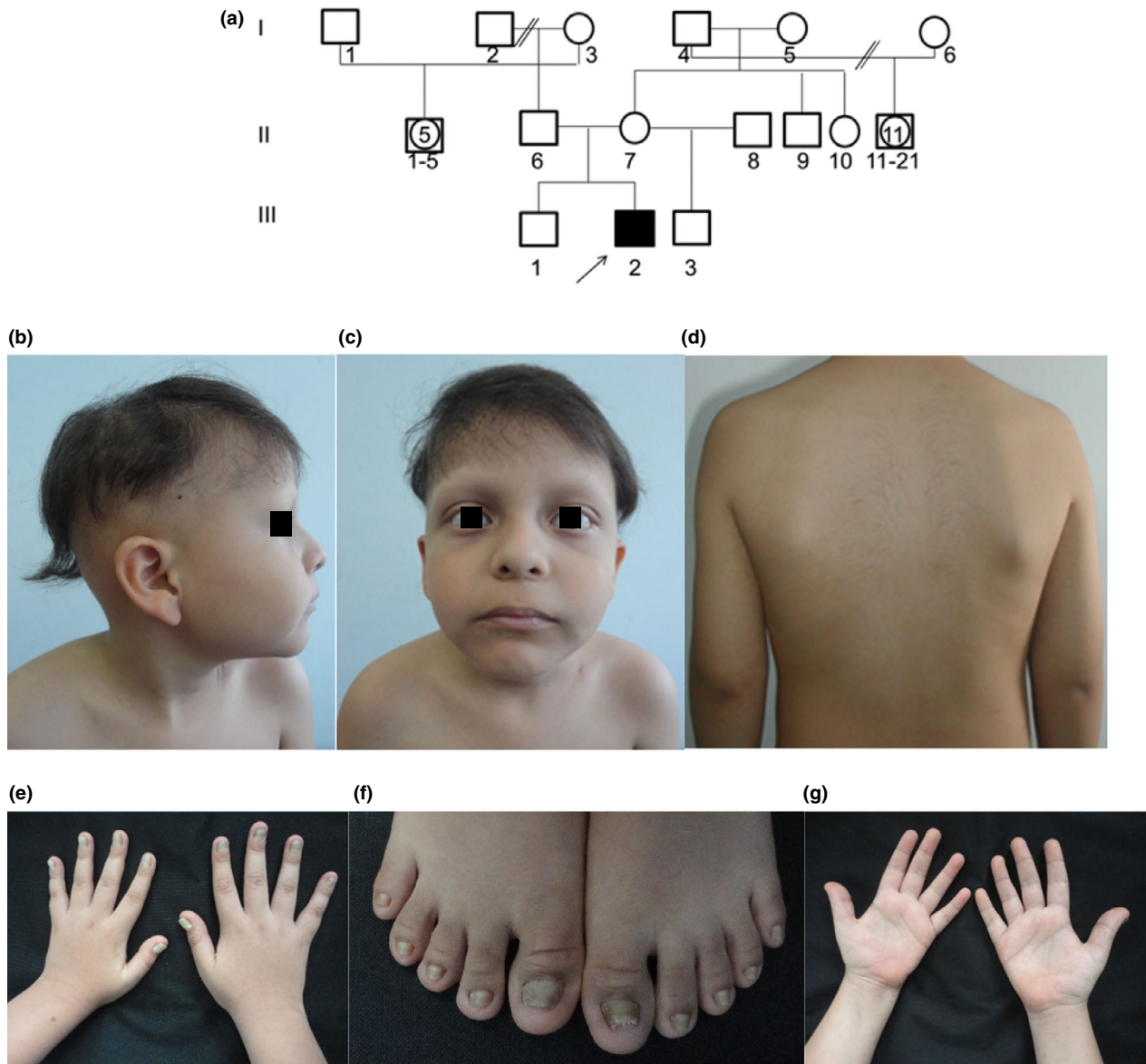
	Lamartine <i>et al.</i> <sup>11</sup>	van Steensel <i>et al.</i> <sup>6</sup>	Marakhonov <i>et al.</i> <sup>12</sup>	Sugiura <i>et al.</i> <sup>5</sup>	Yang <i>et al.</i> <sup>1</sup>	Shi <i>et al.</i> <sup>13</sup>	Present case
Sex	2M/3F	F	F	F	22M/15F	3M/2F	M
Familial case	+	+	+	–	+	+	–
Alopecia	–	–	–	+	36/37	+	–
Sparse hair	+	+	+	–	1/37 <sup>a</sup>	–	+
Nail dystrophy	+	+	+	+	34/37	+	+
Palmar hyperkeratosis	+	+	+	+	21/37	+	–
Plantar hyperkeratosis	+	+	+	+	24/37	+	–
Photophobia	NP	NP	+	+ <sup>b</sup>	NP	NP	–
Sensorineural hearing loss	NP	–	NP	+ <sup>b</sup>	NP	NP	+ <sup>c</sup>
Mental retardation	–	NP	–	NP	NP	NP	–
Additional molecular findings	–	–	–	<i>GJB2</i> c.79G>A, V271	–	<i>GJB2</i> c.109G>A, V371 <sup>d</sup>	–

<sup>a</sup>Slight clinical symptom that is difficult to diagnose.

<sup>b</sup>Associated with the variant found in *GJB2* gene.

<sup>c</sup>Mild sensorineural hearing loss.

<sup>d</sup>Two family members held a heterozygous missense mutation V371 in *GJB2* gene.



**Figure 1** (a) Pedigree of the family, arrow indicates the proband (III:2), the only affected in the family with Clouston syndrome, (b) hair loss in temporo-occipital area, (c) as well as eyebrows and eyelashes and hyperpigmentation in periorbital region, (d) slight hypertrichosis in the posterior thorax, (e and f) fingernails and toenails are whitened, dystrophic, thickened with distal wedge-shaped separation, (g) without palmoplantar keratoderma

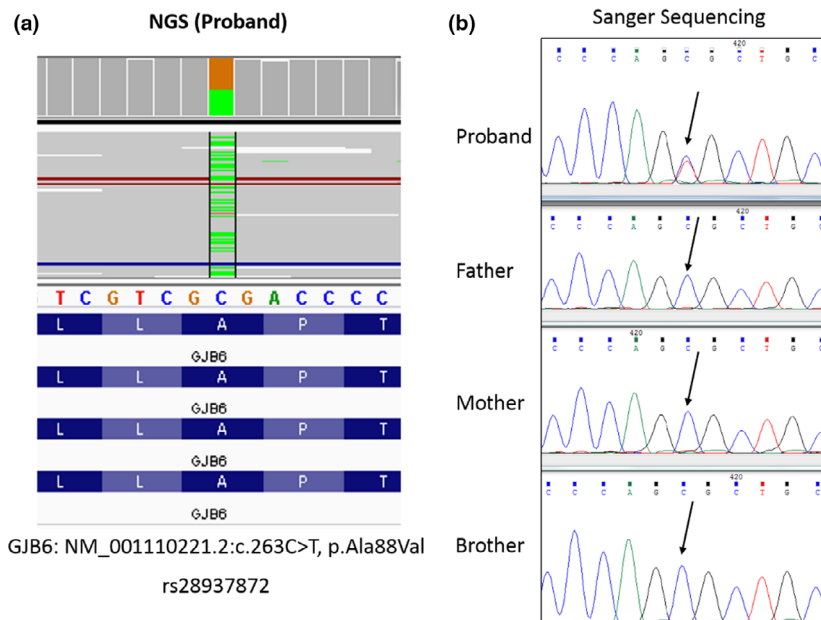
values of 0.991 and 5.988 were obtained, respectively. Values close to 1 in PhastCons and +6 in PhyloP confirm high conservation at this nucleotide, and the alanine at 88 position is highly conserved through different species.

The c.263C>T (A88V) mutation in *GJB6* was first identified in two unrelated French families<sup>11</sup> and was subsequently reported in families from different ethnic populations.<sup>12</sup> The alanine 88 is conserved between human and mouse Cx30,<sup>4</sup> and the introduction of a highly hydrophobic residue (valine, V), in the transmembrane M2 domain, would be expected to change the polarity of connexin channels and intercellular communication<sup>11,13</sup> or induce

Cx30 apoptosis through an endoplasmic reticulum-independent mechanism.<sup>13</sup>

Clinical diagnosis in Clouston syndrome can be delayed in the presence of phenotypic variability resulting in atypical clinical presentation and milder symptoms in younger patients.<sup>3</sup> Molecular genetic investigation is vital, especially in mild or atypical cases, to provide diagnostic accuracy and understand genotype-phenotype correlations.

Multidisciplinary follow-up is paramount to clinical care and can provide control of treatable clinical features, emotional and psychological support, and genetic counseling. Palmoplantar



**Figure 2** (a) Targeted next generation sequencing (NGS) identified the mutation c.263C>T, which shows a cytosine substitution in *GJB6* gene (b) confirmed with Sanger sequencing in the proband, and parents and brother were wild type for the same mutation

keratoderma may develop during childhood and is more severe in older patients.<sup>1,7</sup> Treatment usually focuses on palmoplantar keratoderma with emollients and keratolytic agents, special hair care products, treatment of alopecia, ablation of the nail matrix, and application of artificial nails.<sup>7</sup>

This study reports a sporadic case of Clouston syndrome in a Venezuelan family molecularly confirmed. This case represents the first case of Clouston syndrome described in Venezuela. The clinical characteristics exhibited by the patient were mild possibly because of the young age and characterized by the absence of palmoplantar hyperkeratosis. However, this patient presented hyperpigmentation in the periorbital region that can produce an aspect of aging and slight localized hypertrichosis in the posterior thorax in contrast with the typical findings found in ectodermal dysplasia. This last finding was not associated with the use of medication or any other entity that could justify it. These are novel characteristics previously not reported in literature about Clouston syndrome and as such, expand the phenotype profile.

Francisco Cammarata-Scalisi<sup>1\*</sup>, MD  
Martina Rinelli<sup>2</sup>, PhD  
Elisa Pisaneschi<sup>2</sup>, MD  
Andrea Diociaiuti<sup>3</sup>, MD, PhD  
Colin E. Willoughby<sup>4</sup>, MD, PhD  
Andrea Avendaño<sup>1</sup>, PhD  
Maria C. Digilio<sup>5</sup>, MD  
Antonio Novelli<sup>2</sup>, MD  
Michele Callea<sup>6</sup>, DDS

<sup>1</sup>Unit of Medical Genetics, Department of Pediatrics, Faculty of Medicine, University of the Andes, Merida, Venezuela

<sup>2</sup>Medical Genetics Laboratory, Bambino Gesù Children Hospital and Research Institute, Rome, Italy

<sup>3</sup>Dermatology Unit, Bambino Gesù Children's Hospital, IRCCS, Rome, Italy

<sup>4</sup>Biomedical Sciences Research Institute, Ulster University, Northern Ireland, UK

<sup>5</sup>Department of Medical Genetics and Rare Diseases, Bambino Gesù Children Hospital and Research Institute, Rome, Italy

<sup>6</sup>Unit of Dentistry, Bambino Gesù Children Hospital and Research Institute, Rome, Italy

\*E-mail: francocammarata19@gmail.com

Conflicts of interest: The authors report no potential conflict of interest present, and the work that is reported in this manuscript has not received financial support from any pharmaceutical company or other commercial source.

Late correction added June 10, 2019, after first online publication. Adrea Diociaiuti's name was incorrectly spelled.

doi: 10.1111/ijd.14507

## References

- Yang R, Hu Z, Kong Q, *et al*. A known mutation in *GJB6* in a large Chinese family with hidrotic ectodermal dysplasia. *J Eur Acad Dermatol Venereol* 2016; **30**: 1362–1365.
- Liu YT, Guo K, Li J, *et al*. Novel mutations in *GJB6* and *GJB2* in Clouston syndrome. *Clin Exp Dermatol* 2015; **40**: 770–773.
- Pietrzak A, Grywalska E, Gerkowicz A, *et al*. Immune system disturbances in Clouston syndrome. *Int J Dermatol* 2016; **55**: e241–e249.
- Smith FJ, Morley SM, McLean WH. A novel connexin 30 mutation in Clouston syndrome. *J Invest Dermatol* 2002; **118**: 530–532.

- 5 Sugiura K, Teranishi M, Matsumoto Y, *et al.* Clouston syndrome with heterozygous *GJB6* mutation p.Ala88Val and *GJB2* variant p.Val27Ile revealing mild sensorineural hearing loss and photophobia. *JAMA Dermatol* 2013; **149**: 1350–1351.
- 6 van Steensel MA, Jonkman MF, van Geel M, *et al.* Clouston syndrome can mimic pachyonychia congenita. *J Invest Dermatol* 2003; **121**: 1035–1038.
- 7 Avshalumova L, Fabrikant J, Koriakos A. Overview of skin diseases linked to connexin gene mutations. *Int J Dermatol* 2014; **53**: 192–205.
- 8 Poonawalla T, Xia L, Patten S, *et al.* Clouston syndrome and eccrine syringofibroadenomas. *Am J Dermatopathol* 2009; **31**: 157–161.
- 9 Adzhubei IA, Schmidt S, Peshkin L, *et al.* A method and server for predicting damaging missense mutations. *Nat Methods* 2010; **7**: 248–249.
- 10 Schwarz JM, Rödelserperger C, Schuelke M, *et al.* MutationTaster evaluates disease-causing potential of sequence alterations. *Nat Methods* 2010; **7**: 575–576.
- 11 Lamartine J, Munhoz Essenfelder G, Kibar Z, *et al.* Mutations in *GJB6* cause hidrotic ectodermal dysplasia. *Nat Genet* 2000; **26**: 142–144.
- 12 Marakhonov A, Skoblov M, Galkina V, *et al.* Clouston syndrome: first case in Russia. *Balkan J Med Genet* 2012; **15**: 51–54.
- 13 Shi X, Li D, Chen M, *et al.* *GJB6* mutation A88V for hidrotic ectodermal dysplasia in a Chinese family. *Int J Dermatol* 2019; <https://doi.org/10.1111/ijd.14341>.

## Supporting information

Additional Supporting Information may be found in the online version of this article:

**Table S1.** Panel of ectodermal dysplasia genes.

**Data S1.** Genetic testing.

## Cutaneous hypereosinophilia secondary to a low-grade B-cell lymphoma

Dear Editor,

Hypereosinophilic syndrome is a heterogeneous group of disorders, commonly affecting the skin, characterized by abnormal proliferation and accumulation of eosinophils causing end-organ damage.<sup>1,2</sup> If left untreated, hypereosinophilia is potentially fatal, with a 10-year mortality of up to 50%.<sup>3</sup>

Clonal hypereosinophilia can be myeloproliferative or lymphoproliferative. Myeloproliferative hypereosinophilia is caused by a molecular defect (most commonly the *FIP1L1/PDGFR* fusion gene) at the progenitor stem cell level of eosinophil differentiation in the bone marrow, leading to clonal expansion of eosinophils.<sup>4,5</sup>

Lymphoproliferative hypereosinophilia is usually associated with abnormal T-cell clones which stimulate the production of eosinophilopoietic cytokines including IL-4 and IL-5.<sup>6</sup> Hypereosinophilia associated with B-cell neoplasia is only occasionally reported and tends to be in the context of B-cell non-Hodgkin's lymphoma.<sup>7</sup>

We describe an unusual case of cutaneous hypereosinophilia driven by a low-grade B-cell lymphoma, which was successfully treated with rituximab.

A 58-year-old male presented with a 2-week history of a generalized pruritic rash, on a background of night sweats, fatigue, and weight loss over the preceding 6 months. Clinical examination revealed a bright red raised confluent rash from head to toe, with sparing of the inframammary and periumbilical region (Fig. 1). There was splenomegaly and generalized lymphadenopathy.

Laboratory investigations of peripheral blood demonstrated an elevated white cell count  $12.5 \times 10^9/l$  (normal: 4–10), elevated eosinophil count  $7.6 \times 10^9/l$  (normal: 0.02–0.5), raised CRP 78 mg/l (normal: 0–5), and increased levels of IgE 744 kU/l (normal: 0–100) and IgG 29.8 g/l (normal: 6.8–15.3). Serum tryptase level was normal. Radiological investigation confirmed splenomegaly and widespread lymphadenopathy. Skin biopsy demonstrated an eosinophil-rich inflammation (Fig. 2). Infective and autoimmune screens were negative.

Differential diagnosis included a drug reaction with eosinophilia and systemic symptoms (DRESS), Churg-Strauss, a hematologic malignancy – particularly a myeloproliferative or T-cell lymphoproliferative disorder – or idiopathic hypereosinophilia.

A lymph node biopsy demonstrated reactive changes but no evidence of malignancy. Bone marrow aspirate showed hypereosinophilia but no atypia. FISH analysis for the *FIP1L1/PDGFR* fusion gene was negative, and no clonal T-cell receptor gene rearrangements were detected. Subsequent peripheral blood flow cytometry revealed clonal B-cell proliferation suggestive of a low-grade B-cell lymphoma.

The patient was diagnosed with hypereosinophilia secondary to a low-grade B-cell lymphoma. High-dose systemic steroids were commenced with resolution of the patient's cutaneous and systemic symptoms. Attempts to wean steroid therapy resulted in symptom recurrence (Fig. 1).

The monoclonal antibody rituximab was administered (375 mg/m<sup>2</sup> once weekly) for a 4-week period to target the clonal B-cell population driving the hypereosinophilia. Subsequently steroids were successfully weaned, the rash resolved, and eosinophil count was normalized. Radiological follow-up at 1 year confirmed the absence of lymphadenopathy and splenomegaly. Follow-up includes 6-month review with full blood counts. Five years later, he remains asymptomatic.

Hypereosinophilia is a complex multisystem condition. Lymphoproliferative hypereosinophilia is usually driven by T-cell malignancies, but cases have been described in relation to B-cell non-Hodgkin's lymphoma.<sup>7</sup> This case is unusual because the hypereosinophilia was driven by a low-grade B-cell lymphoma and demonstrates the importance of hematological input and blood flow or bone marrow cytometry in patients with hypereosinophilia.

Prolonged hypereosinophilia causes tissue damage. Early diagnosis and treatment are vital to limit end-organ damage and