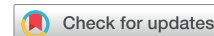

## GYNECOLOGY

# Diagnostic performance of ultrasound in assessing the extension of disease in advanced ovarian cancer



Maria Cristina Moruzzi, MD; Giulia Bolomini, MD; Rosanna Esposito, MD; Floriana Mascilini, MD, PhD; Francesca Ciccarone, MD; Lorena Quagliozzi, MD; Maria Teresa Giudice, MD; Giuliana Beneduce, MD; Silvia Ficarelli, MD; Rossana Moroni, MS; Giovanni Scambia, MD, PhD; Anna Fagotti, MD, PhD; Antonia Carla Testa, MD, PhD; Francesca Moro, MD, PhD

**BACKGROUND:** Surgical exploration remains the gold standard for evaluating the extension of disease and predicting resectability. A laparoscopy-based scoring model was developed by Fagotti and colleagues in 2006 and updated in 2015, based on the intraoperative presence or absence of some specific cancer features. The model proved an overall accuracy rate of 77% to 100% and is considered the reference test for assessing resectability in our institution.

**OBJECTIVE:** The primary aim of the study was to analyze the agreement between preoperative ultrasound examination and laparoscopic findings in assessing the extension of intraabdominal disease using 6 parameters described by Fagotti's score.

**STUDY DESIGN:** This was a prospective single-center observational study. Between January 2019 and June 2020, consecutive patients with clinical or radiological suspicion of ovarian or peritoneal cancer were assessed with preoperative ultrasound examination and assigned a score based on the 6 Fagotti score parameters (great omentum, liver surface, lesser omentum/stomach/spleen, parietal peritoneum, diaphragms, bowel disease). Presence of mesenteral retraction of the small bowel and miliary

carcinomatosis on the serosa were also evaluated. Each parameter was correlated with laparoscopic findings. Concordance was calculated between ultrasound and laparoscopic parameters using Cohen's kappa.

**RESULTS:** Cohen's kappa ranged from 0.70 to 0.90 for carcinomatosis on the small or large bowel, supracolic omentum, liver surface, and diaphragms. Cohen's kappa test was lower for carcinomatosis on the parietal peritoneum ( $k=0.63$ ) and on the lesser omentum or lesser curvature of the stomach or spleen ( $k=0.54$ ). The agreement between ultrasound and surgical predictive index value (score) was  $k=0.74$ . For the evaluation of mesenteral retraction and miliary carcinomatosis, the agreement was low ( $k=0.57$  and  $k=0.36$ , respectively).

**CONCLUSION:** The results of ultrasound and laparoscopy in the assessment of intraabdominal tumor spread were in substantial agreement for almost all the parameters. Ultrasound examination can play a useful role in the preoperative management of patients with ovarian cancer when used in dedicated referral centers.

**Key words:** laparoscopy, ovarian cancer, staging, ultrasound

## Introduction

Ovarian cancer is the eighth most common cancer among women in the developed world,<sup>1</sup> with a 30% to 45% 5-year survival rate. Unfortunately, in approximately 80% of women it is diagnosed at an advanced stage, when intraperitoneal dissemination has occurred.<sup>2</sup> Surgical outcome in terms of macroscopic residual disease after surgery heavily affects patient prognosis,<sup>3,4</sup> with complete cytoreduction (no residual tumor) being associated with the best overall and disease-free survival.<sup>5</sup>

However, aggressive surgical procedures, required to achieve optimal cytoreduction, may result in severe medical consequences and may have a negative impact on patients' quality of life and reduce chances of receiving timely chemotherapy.

In patients judged unsuited for optimal cytoreduction (residual disease measuring  $<1$  cm), neoadjuvant chemotherapy followed by interval debulking surgery could be an appropriate alternative choice.<sup>6,7</sup> Accurate preoperative assessment of tumor burden is fundamental in defining a tailored therapeutic approach and in appropriately informing the patient. Different diagnostic methods for preoperative assessment of disease extension have been developed, mostly based on imaging and tumor serum markers. However, surgical exploration remains the gold standard for predicting resectability.<sup>8</sup>

A laparoscopy-based scoring model based on the intraoperative presence or

absence of some specific cancer features (predictive index value [PIV]) was developed by Fagotti and colleagues in 2006<sup>9,10</sup> and updated in 2015.<sup>11</sup> The model demonstrated an overall accuracy rate between 77.3% and 100%. At a PIV  $>8$ , the probability of optimally resecting the disease at laparotomy was 0, and the rate of unnecessary exploratory laparotomy was 40.5%.<sup>11</sup>

Computed tomography (CT) is currently the most widely used imaging technique for the preoperative staging of ovarian cancer, with a reported accuracy ranging from 70% to 90%. Recently, an ESGO/ISUOG/IOTA/ESGE Consensus Statement included ultrasound examination performed by an expert examiner among approaches for the preoperative diagnosis of ovarian tumors and assessment of disease spread.<sup>12</sup> In fact, when performed systematically by an expert examiner, a combined transvaginal and transabdominal ultrasound scan can provide accurate information about all

**Cite this article as:** Moruzzi MC, Bolomini G, Esposito R, et al. Diagnostic performance of ultrasound in assessing the extension of disease in advanced ovarian cancer. *Am J Obstet Gynecol* 2022;227:601.e1-20.

0002-9378/\$36.00

© 2022 Elsevier Inc. All rights reserved.

<https://doi.org/10.1016/j.ajog.2022.05.029>



Click [Video](#) under article title in Contents at [ajog.org](#)

## AJOG at a Glance

**Why was this study conducted?**

Few data are available in the literature regarding the accuracy of ultrasound in detecting intraabdominal ovarian cancer spread and the estimation of the probability of optimal cytoreduction.

**Key findings**

The results of ultrasound and laparoscopy in the assessment of intraabdominal tumor spread were in substantial agreement for almost all the parameters.

**What does this add to what is known?**

This study proposed strategies for the management of patients with advanced ovarian cancer. For example, ultrasound examination could be an alternative diagnostic tool to computed tomography (CT) for patients allergic to contrast media. Imaging methods (ultrasound examination or CT) could be useful in cases of patients unsuitable for diagnostic surgery because of severe comorbidities or clear evidence of advanced unresectable disease, and for performing biopsies for quick histologic diagnosis and molecular profiling.

the possible pelvic and abdominal sites of ovarian tumor spread.<sup>13–15</sup> Ultrasound is also able to detect metastatic inguinal lymph nodes with high sensitivity (100%) and specificity (99%), and to detect metastatic retroperitoneal lymph nodes with high specificity (93%–99%) but low sensitivity (32%–34%).<sup>14,16</sup> Ultrasound also has several advantages. It is a noninvasive and inexpensive imaging method that can be carried out without any risk or discomfort to the patient. It is a dynamic and interactive examination able to provide information on how pelvic and abdominal structures move in relation to each other. However, few data are available in the literature regarding the accuracy of ultrasound in detecting intraabdominal ovarian cancer spread and the estimation of probability of optimal cytoreduction.<sup>14,17</sup>

The primary aim of the study was to analyze the agreement between preoperative ultrasound examination and laparoscopic findings in assessing the extension of intraabdominal disease using 6 parameters described by Fagotti's score (or PIV score). Laparoscopic findings according to Fagotti's score were used as the reference standard. The secondary aims were to evaluate: (1) the ability of ultrasound to assess the presence or absence of intraabdominal disease using 6 parameters described by

Fagotti's score; and (2) the agreement between preoperative ultrasound examination and laparoscopic findings in defining the score.

## Materials and Methods

### Study design

This was a single-center prospective observational study conducted at Fondazione Policlinico Universitario Agostino Gemelli, Istituto di Ricovero e Cura a Carattere Scientifico, in Rome, Italy. The local ethics committee approved the study protocol (protocol number 28967/18; ID: 2172),<sup>18</sup> and informed written consent was obtained from all participants.

Patients were consecutively enrolled in the study between January 2019 and June 2020.

Eligibility criteria were: (1) patients with a pelvic mass and at least 1 visible suspicious lesion outside the pelvis detected at imaging (ultrasound, CTscan or magnetic resonance imaging [MRI]), (2) patients with a pelvic mass and cancer antigen (CA) 125 level >500 UI/mL, or (3) patients with ascites and CA-125 level >500 UI/mL. Other inclusion parameters were Eastern Cooperative Oncology Group performance status <3 and age of 18 to 75 years. The exclusion criteria were: concurrent known malignancies at other sites; medical problems (for example, uncontrolled severe

infection) that would limit full compliance with the study; previous major surgery on stomach or bowel; patient's refusal to provide informed consent; and current pregnancy.

For each patient enrolled in the study, clinical data (age, parity, menopausal status, body mass index [BMI], serum tumor markers value, type of symptoms) and information on surgery, histology, and International Federation of Gynecology and Obstetrics (FIGO) staging were prospectively collected in a data collection system (REDCap software; Vanderbilt University, Nashville, TN).

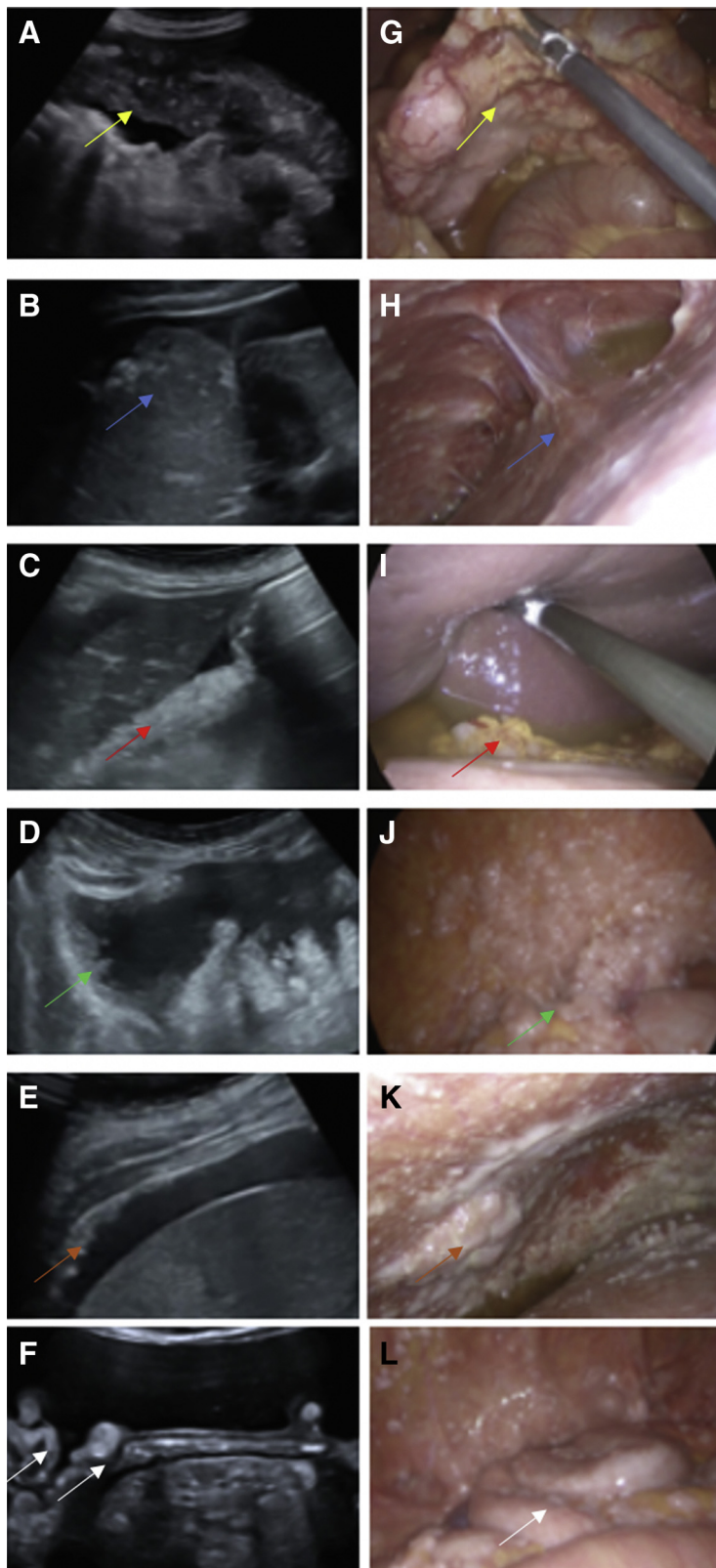
**Ultrasound examination**

All patients included in the study underwent preoperative transvaginal and transabdominal ultrasound examinations, with high-end ultrasound equipment: GE Medical System Voluson E10 instrument (GE Healthcare, Waukesha, WI) (transvaginal transducer of 4–9 MHz and transabdominal transducer of 1–6 MHz); HERA I10 instrument (Samsung Medison Co, Ltd, Seoul, Republic of Korea) (transvaginal transducer of 3–10 MHz and transabdominal transducer of 1–7 MHz); and Aplio i700 instrument (Canon Medical Systems Corporation, Tokyo, Japan) (transvaginal transducer of 7.5–9 MHz and transabdominal transducer of 3–8 MHz).

The presence or absence of specific cancer features according to the laparoscopy-based scoring model (PIV) described by Fagotti and colleagues were evaluated.<sup>11</sup> This laparoscopy-based scoring model (range, 0–12) is the reference test in our institution for assessing resectability. Disease of patients with PIV scores ≤8 is considered resectable, and these patients are candidates for primary debulking surgery. Those with scores >8 are triaged to standard neoadjuvant chemotherapy or clinical trials.

Ultrasound parameters corresponding to PIV laparoscopic features are described as follows (Figure 1):

1. Great omentum: a score of 2 was given in the presence of thickened omentum suggesting omental cake (ie, vascularized nodules in echogenic

**FIGURE 1****Ultrasound and corresponding laparoscopic parameters included in the PIV score**

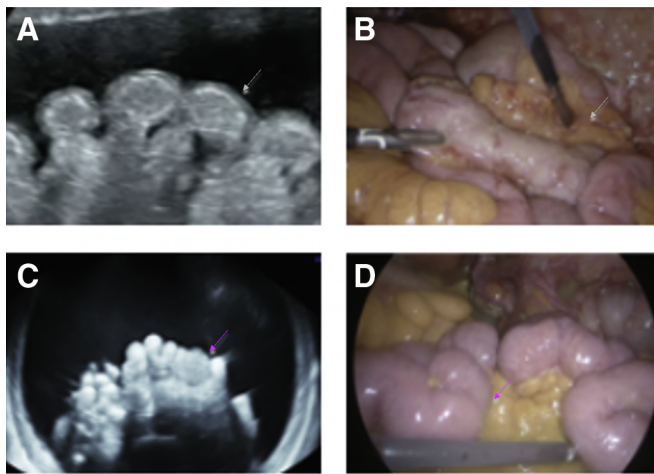
omental tissue or diffuse inhomogeneous solid nonperistaltic strand of tissue with free caudal margin) located between the stomach and the transverse colon.

2. Carcinomatosis on the liver: a score of 2 was given in the case of any single lesion  $>2$  cm on the liver capsule.
3. Lesser omental carcinomatosis and/or visceral carcinomatosis on the small curvature of the stomach and/or visceral carcinomatosis on the spleen: a score of 2 was given in the case of thickening or nodules in the lesser omentum and/or in the small curvature of the stomach and/or in the spleen.
4. Parietal peritoneal involvement of the paracolic gutter(s) and/or the anterior abdominal wall: a score of 2 was given in the case of diffuse “sheet-like” hypoechoogenic thickening or hypoechoogenic confluent nodules of the peritoneal abdominal wall and/or paracolic gutters.
5. Parietal peritoneal involvement on the diaphragms: a score of 2 was given in the case of diffuse “sheet-like” hypoechoogenic thickening and/or confluent nodules on most of the diaphragmatic surface. In the case of isolated nodules, a score of 2 was given only if nodules  $>2$  cm were bilateral.
6. Carcinomatosis on the small and large bowel (except rectosigmoid): a score of 2 was given in the case of hypoechoogenic thickening or hypoechoogenic confluent nodules that seemed to infiltrate the bowel wall (excluding rectosigmoid involvement).

If each parameter was negative (no neoplastic involvement), a score of 0 was assigned, whereas parameters that were not correctly evaluable were recorded as “not assessable” (NA). A PIV score was also calculated at ultrasound examination, ranging from 0 to 12.

In addition, suspicious mesenteric retraction of the small bowel and miliary carcinomatosis on the serosa of the small bowel (Figure 2) were evaluated. Both are considered absolute criteria of unresectability when found during

**FIGURE 2**  
**Ultrasound and corresponding laparoscopic parameters considered absolute criteria of unresectability**



Images showing ultrasound and corresponding laparoscopic parameters considered absolute criteria of unresectability including: **A, C**, mesenteric retraction (*gray arrows*) and **B, D**, miliary carcinomatosis on the serosa of the small bowel (*purple arrows*).

Moruzzi. *Ultrasound in preoperative staging of advanced ovarian cancer. Am J Obstet Gynecol* 2022.

surgery. Miliary carcinomatosis on ultrasound was considered to be present when observing diffuse carcinomatosis on the serosa of the small bowel. This parameter is assessed subjectively, and no specific cutoff for carcinomatosis thickness has been predefined. Mesenteric retraction on ultrasound was considered to be present in the case of a subjective evaluation of “fixity” or “hypomobility” of bowel loops toward the mesenteric root, with “cauliflower” appearance.<sup>13</sup> [Supplemental Videos 1 to 10](#) demonstrate examples of disease in the PIV score sites and examples of mesenteric retraction and miliary carcinomatosis. All videos include 3D models and corresponding parameters at ultrasound and laparoscopy.

At ultrasound examination, any adnexal mass was described according to

International Ovarian Tumor Analysis terminology.<sup>19</sup> In the case of bilateral adnexal masses, the one with the most complex ultrasound morphology, or the largest one in the case of similar morphology, was considered in our analysis. All ultrasound examinations were performed by expert examiners, skilled in gynecologic oncology and with >10 years of experience in ultrasound (M.C.M., F.M., F.M., and G.B.). A complete ultrasound examination to assess all parameters takes approximately 40 minutes.

### Surgical procedure

During laparoscopy, each parameter was systematically investigated and described according to Fagotti’s score, as previously reported.<sup>11</sup> If the evaluated parameter was negative (no neoplastic involvement), a score of 0 was given,

whereas parameters that were not correctly evaluable were recorded as NA. The presence of miliary carcinomatosis and mesenteric retraction was also reported. Six surgeons were involved in laparoscopic evaluation, and they were not blinded to ultrasound findings. A second opinion was required from another experienced surgeon for each assessment to decide together the feasibility of cytoreductive surgery. Time lapse between ultrasound examination and laparoscopy was  $\leq 3$  days.

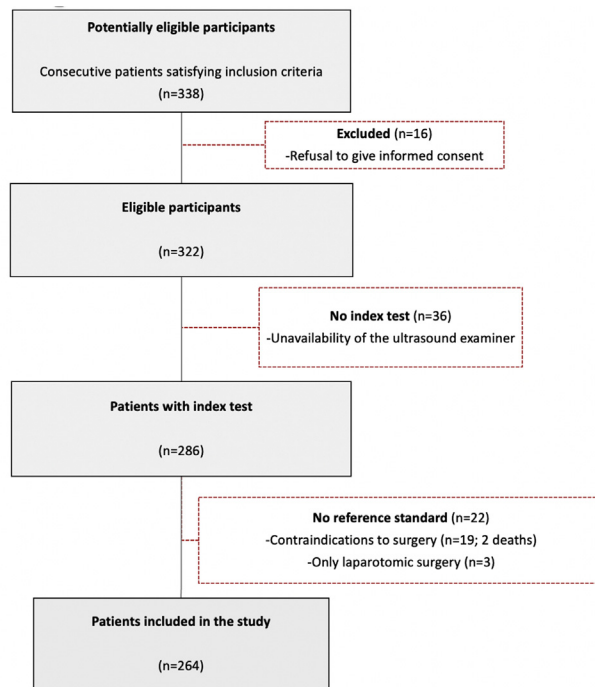
Ultrasound digital images and videos of each ultrasound parameter and surgical videos of each laparoscopic evaluation were collected and stored. Both ultrasound examiners and surgeons completed a predefined form including all PIV parameters, immediately after ultrasound and surgery examinations, respectively ([Supplemental Figures 1 and 2](#)). The results were then reported into REDCap by data entry assistants.

### Statistical methods

For the primary objective of the study, a sample size of  $N=240$  patients was required to detect a Cohen’s kappa value of 0.90, with  $\alpha=0.05$ . Quantitative variables were described using the median and range, whereas qualitative variables were summarized with absolute and percentage frequency tables. The ability of ultrasound examination to assess each PIV parameter is defined as the proportion of cases in which that parameter was assessable. For example, at ultrasound examination, the omentum could be diagnosed as assessable (infiltrated or not infiltrated) or NA. The agreement between ultrasound and surgical parameters was evaluated using Cohen’s kappa. Interpretation of Cohen’s index was performed according to Landis and Koch:  $\leq 0.00$  indicating no agreement, 0.00 to 0.20 slight, 0.21 to 0.40 fair, 0.41 to 0.60 moderate, 0.61 to 0.80 substantial, and 0.81 to 1.00 almost perfect agreement.<sup>20</sup> Sensitivity, specificity, positive likelihood ratio, and negative likelihood ratio were provided with the corresponding 95% confidence intervals. For the calculation of PIV score, parameters NA at imaging or laparoscopy were given a value of 0.

Images showing ultrasound and corresponding laparoscopic parameters included in the predictive index value score: omental cake (*yellow arrows*) **A**, at ultrasound and **G**, at laparoscopy; lesion on the surface of the liver (*blue arrows*) **B**, at ultrasound and **H**, at laparoscopy; thickening lesser omentum indicative of lesser omental carcinomatosis (*red arrows*) **C**, at ultrasound and **I**, at laparoscopy; diffuse sheet-like hypoechogetic thickening of paracolic gutter (*green arrows*) **D**, at ultrasound and **J**, at laparoscopy; diffuse sheet-like hypoechogetic thickening of the diaphragmatic surface (*orange arrows*) **E**, at ultrasound and **K**, at laparoscopy; confluent nodules infiltrating bowel wall (*white arrows*) **F**, at ultrasound and **L**, at laparoscopy.

Moruzzi. *Ultrasound in preoperative staging of advanced ovarian cancer. Am J Obstet Gynecol* 2022.

**FIGURE 3**  
**Flow diagram**

Moruzzi. Ultrasound in preoperative staging of advanced ovarian cancer. *Am J Obstet Gynecol* 2022.

Patients were divided according to PIV score  $\leq 8$  or  $> 8$ , with  $> 8$  being indicative of unresectability. The significance level was set at  $P < .05$ .

## Results

A total of 338 consecutive patients were enrolled in the study, but 264 women were finally included in the analysis (Figure 3). Clinical, surgical, and histologic characteristics of the study population are shown in Table 1. The median age at diagnosis was 58 years (range, 25–75), and 181 of 264 (68.6%) women were postmenopausal. The median serum CA-125 levels were 1907.18 U/mL (range, 1.00–20,278.00). At surgery, 114 (43.2%) patients underwent diagnostic procedures with biopsies, whereas 150 (56.8%) underwent debulking surgery. In 233 (88.3%) patients, final histology was positive for primary invasive ovarian cancer; 19 (7.2%) patients had ovarian metastases from other primary tumors (mainly derived from gastrointestinal malignancies), 6 (2.6%) had serous borderline ovarian tumors, and 6 (2.6%)

had benign tumors. Among primary invasive ovarian malignancies, most were diagnosed at FIGO stage III (163/233, 70.0%) and FIGO stage IV (47/233, 20.2%).

At ultrasound examination, ascites was present in 202 of 264 (76.5%) cases, and pelvic masses were detected in 253 of 264 (95.8%) patients. The masses were bilateral in 173 of 253 (68.3%) cases (Supplemental Table). Ultrasound and laparoscopic findings are shown in Table 2. Great omentum was the most frequent parameter described as involved by both methods (193/264, 73.1% at ultrasound examination; 189/264, 71.6% at laparoscopy), followed by the diaphragms and parietal peritoneum.

Ultrasound examination was able to identify carcinomatosis on the small or large bowel in all cases. The great omentum, liver surface, the lesser omentum or small curvature of the stomach or spleen surface, the parietal peritoneum (including paracolic gutters and abdominal wall), and diaphragms

were NA in 3 of 264 (1.1%), 8 of 264 (3.0%), 46 of 264 (17.4%), 6 of 264 (2.3%), and 7 of 264 (2.7%) cases, respectively. Laparoscopy was able to evaluate the great omentum and the small and large bowel in all cases. Liver surface, the lesser omentum or small curvature of the stomach or spleen surface, the parietal peritoneum (including paracolic gutters and abdominal wall), and diaphragms were classified as NA in 1 of 264 (0.4%), 24 of 264 (9.1%), 5 of 264 (1.9%), and 1 of 264 (0.4%) cases, respectively (Table 2).

Cohen's kappa ranged from 0.70 to 0.90 for carcinomatosis on the small or large bowel, supracolic omentum, liver surface, and diaphragms. Cohen's kappa test was lower for carcinomatosis on the parietal peritoneum ( $k=0.63$ ) and on the lesser omentum or lesser curvature of the stomach or spleen ( $k=0.54$ ). The agreement between ultrasound and surgical PIV was  $k=0.74$  (Table 3). For the evaluation of mesenteric retraction and miliary carcinomatosis, the agreement was low ( $k=0.57$  and  $k=0.36$ , respectively). The accuracy of ultrasound in evaluating the 6 PIV parameters ranged from 77.8% to 95.5% (Table 4). Ultrasound had high sensitivity ( $>90\%$ ) for 3 of the 6 parameters included in the PIV score (supracolic omentum, parietal peritoneum, and small or large bowel) and good sensitivity ( $>80\%$ ) for 1 parameter (diaphragms). However, sensitivity was low for 2 parameters (liver surface and lesser omentum or lesser curvature of the stomach or spleen). The specificity was high ( $>90\%$ ) for 2 of the 6 parameters (liver surface and small or large bowel) and good ( $>80\%$ ) for 3 parameters (supracolic omentum, lesser omentum or lesser curvature of the stomach or spleen, and diaphragms). It was moderate for only 1 parameter (parietal peritoneum).

Both the agreement between ultrasound and laparoscopic findings, and the performance of ultrasound in the assessment of the 6 PIV parameters in the subset of obese women (BMI  $> 30$ ;  $n=42$ ) are reported in Supplemental Table 2. In this subgroup, agreement was lower than in the whole population

**TABLE 1**  
**Clinical, surgical, and histologic characteristics of the study population**

Characteristic	All (n=264)
Age (y)	58 (25–75)
BMI	25 (10–54)
Previous surgical treatment	
Hysterectomy	10 (3.8)
Oophorectomy	2 (0.8)
CA-125 (U/mL) <sup>a</sup>	1907.18 (1.00–20,278.00)
CA-19.9 (U/mL) <sup>b</sup>	237.35 (0.80–20,000.00)
CEA (U/mL) <sup>c</sup>	15.10 (0.00–1313.00)
CA-15.3 (U/mL) <sup>d</sup>	1943.21 (3.00–229,400.00)
CA-125/CEA ratio <sup>e</sup>	1319.42 (0.40–9053.60)
Type of surgery	
Exploratory surgery	114/264 (43.2)
Laparoscopy only	107/114 (93.8)
Laparoscopy and laparotomy	7/114 (6.1)
Cytoreductive surgery	150/264 (56.8)
Laparoscopy only	2/150 (1.3)
Laparoscopy and laparotomy	148/150 (98.6)
RT at cytoreductive surgery <sup>f</sup>	
Complete cytoreduction (RT=0)	139/147 (94.5)
Minimal residual disease (RT≤10 mm)	6/147 (4.0)
Suboptimal cytoreduction (RT>10 mm)	2/147 (1.36)
Histology	
High-grade serous ovarian cancer	206 (78.0)
Other primary ovarian cancer <sup>g</sup>	27 (10.3)
Metastatic ovarian cancer <sup>h</sup>	19 (7.2)
Other <sup>i</sup>	12 (4.5)
FIGO stage if primary ovarian cancer	
Stage I	14/233 (6.0)
Stage II	8/233 (3.4)
Stage III	163/233 (70.0)
Stage IV	47/233 (20.2)
Not applicable (metastatic or borderline histology)	32/264 (12.1)

Data are presented as number (percentage) or number/total number (percentage).

BMI, body mass index; CA, cancer antigen; CEA, carcinoembryonic antigen; FIGO, International Federation of Gynecology and Obstetrics; RT, residual tumor.

<sup>a</sup> Data available in 238 of 264 cases; <sup>b</sup> Data available in 163 of 264 cases; <sup>c</sup> Data available in 143 of 264 cases; <sup>d</sup> Data available in 131 of 264 cases; <sup>e</sup> Data available in 70 of 264 cases; <sup>f</sup> Data available in 147 of 150 cases; <sup>g</sup> Low-grade serous histology in 5 cases, endometrioid histology in 10 cases, clear-cell histology in 5 cases, mixed malignant mesodermal tumor (carcinosarcoma) in 4 cases, neuroendocrine tumor in 1 case, adult-type granulosa cell tumor in 1 case, ovarian mesothelioma in 1 case; <sup>h</sup> Metastatic ovarian cancer from gastrointestinal/biliary tract primary in 17 cases, breast primary in 2 cases; <sup>i</sup> Six cases of serous borderline ovarian tumor (4 with invasive implants), 3 ovarian fibromas (2 with Meigs' syndrome), 1 ovarian endometrioma, and 2 cystadenofibromas.

Ultrasound in preoperative staging of advanced ovarian cancer. *Am J Obstet Gynecol* 2022.

in the assessment of great omentum, liver surface, and parietal peritoneum. Agreement and performance of ultrasound in the subset of women with primary advanced ovarian cancer at histology (n=210) are reported in [Supplemental Table 3](#). In this subgroup, agreement was lower than in the whole population only in the evaluation of diaphragms. Finally, we analyzed the agreement between ultrasound and laparoscopy, and the performance of ultrasound using laparoscopy as the reference standard in the subset of women who underwent laparotomic cytoreduction (n=148) ([Supplemental Table 4](#)). The agreement between ultrasound and laparoscopy was similar to the agreement between ultrasound and laparoscopy in whole series for almost all the parameters except parietal peritoneum.

## Comment

### Principal findings

In the present study, we explored the agreement of ultrasound examination with laparoscopic findings in assessing the extension of intraabdominal disease using 6 parameters as described by Fagotti's score. The results of ultrasound and laparoscopy were in substantial agreement for almost all the investigated parameters. However, the assessable rate was higher for laparoscopy than ultrasound for all parameters, except for the spleen. Ultrasound showed good to high sensitivity (>80%) in the assessment of carcinomatosis on the great omentum, parietal peritoneum, diaphragms, and small or large bowel, but low sensitivity in the evaluation of the liver surface and lesser omentum or lesser curvature of the stomach or spleen. The specificity of ultrasound in the detection of all evaluated parameters except the parietal peritoneum was >80%.

### Results in the context of what is known

Other studies have evaluated the performance of ultrasound examination in assessing spread of disease. For example, in our previous study including 147 patients with advanced ovarian cancer,<sup>13</sup> we demonstrated that ultrasound

**TABLE 2**  
**Distribution of involved intraperitoneal sites and ability of ultrasound and laparoscopic examinations in assessing predictive index value parameters in 264 patients with suspected advanced ovarian cancer**

Parameter	Ultrasound	Laparoscopy
Supracolic omentum disease		
Involved	193 (73.1)	189 (71.6)
Not involved	68 (25.7)	75 (28.4)
NA	3 (1.1)	0 (0)
Visceral carcinomatosis on the liver		
Involved	63 (23.9)	84 (31.8)
Not involved	193 (73.1)	179 (67.8)
NA	8 (3.0)	1 (0.4)
"Lesser omental carcinomatosis/visceral carcinomatosis on the lesser curvature of the stomach/visceral carcinomatosis on the spleen" compound parameter <sup>a</sup>		
Positive	86 (32.6)	109 (41.3)
Negative	132 (50.0)	131 (49.6)
NA	46 (17.4)	24 (9.1)
Lesser omental carcinomatosis		
Involved	65 (24.6)	78 (29.5)
Not involved	141 (53.4)	156 (59.1)
NA	58 (22.0)	30 (11.4)
Visceral carcinomatosis on the lesser curvature of the stomach		
Involved	17 (6.4)	50 (18.9)
Not involved	193 (73.1)	192 (72.7)
NA	54 (20.5)	22 (8.4)
Visceral carcinomatosis on the spleen		
Involved	31 (11.7)	41 (15.5)
Not involved	199 (75.4)	132 (50.0)
NA	34 (12.9)	91 (34.5)
"Parietal peritoneal involvement" compound parameter <sup>b</sup>		
Positive	164 (62.1)	134 (50.8)
Negative	94 (35.6)	125 (47.3)
NA	6 (2.3)	5 (1.9)
Parietal peritoneum involvement of the right paracolic gutter		
Involved	127 (48.1)	126 (47.7)
Not involved	108 (40.9)	133 (50.4)
NA	29 (11.0)	5 (1.9)
Parietal peritoneum involvement of the left paracolic gutter		
Involved	132 (50.0)	124 (47.0)
Not involved	98 (37.1)	134 (50.7)

Ultrasound in preoperative staging of advanced ovarian cancer. *Am J Obstet Gynecol* 2022.

(continued)

examination had high sensitivity and specificity in assessing omental and parietal peritoneum involvement. However, no other PIV parameters were considered.

The largest prospective series was reported by Fischerova and colleagues.<sup>14</sup> They studied the accuracy of ultrasound in assessing pelvic and intra-abdominal spread in 394 patients with ovarian cancer (291 at advanced stage). In particular, they assessed the following abdominal sites: diaphragms, surface of the liver and spleen, peritoneal surface of the abdominal wall or paracolic gutters, omentum, visceral peritoneum of the small or large bowel, and mesentery of the intestine or colon. They reported that ultrasound examination had high specificity in assessing disease in all these parameters with lower sensitivity (67.3% for omentum disease, 30.8% for parietal peritoneal involvement on the diaphragms, 82.5% for carcinomatosis of peritoneal surfaces on the abdominal wall or paracolic gutters, and 44.9% for visceral carcinomatosis on the small or large bowel). We confirmed similar sensitivity in assessing peritoneal surfaces on the abdominal wall or paracolic gutters, but we obtained better sensitivity in assessing omentum disease and parietal peritoneal involvement on the diaphragms. It is difficult to explain the difference in sensitivity values of some parameters between our study and the 2017 study by Fischerova. It could depend on the different type of population (ie, the prevalence of positive cases). It is also important to note that in the last 10 years, the methodology has been further refined, as demonstrated by the improved results of Fischerova in 2022.<sup>17</sup>

In recent years, ultrasound examination in preoperative staging of ovarian cancer has gained importance in the literature and in clinical practice, especially in gynecologic oncology referral centers. Some authors have compared the performance of ultrasound examination with that of CT scans in the identification of disease spread. In particular, in a retrospective study by Alcazar et al,<sup>21</sup> the diagnostic performance of ultrasound was compared with that of CT in the preoperative

TABLE 2

**Distribution of involved intraperitoneal sites and ability of ultrasound and laparoscopic examinations in assessing predictive index value parameters in 264 patients with suspected advanced ovarian cancer** (continued)

Parameter	Ultrasound	Laparoscopy
NA	34 (12.9)	6 (2.3)
Peritoneum involvement of the abdominal wall		
Involved	42 (15.9)	88 (33.3)
Not involved	201 (76.1)	169 (64.0)
NA	21 (8.0)	7 (2.7)
"Parietal peritoneal involvement of the diaphragms" compound parameter <sup>c</sup>		
Positive	174 (65.9)	183 (69.3)
Negative	83 (31.4)	80 (30.3)
NA	7 (2.7)	1 (0.4)
Parietal peritoneal involvement of the right diaphragm		
Involved	163 (61.7)	178 (67.4)
Not involved	91 (34.5)	81 (30.7)
NA	10 (3.8)	5 (1.9)
Parietal peritoneal involvement of the left diaphragm		
Involved	103 (39.0)	120 (45.4)
Not involved	138 (52.3)	139 (52.7)
NA	23 (8.7)	5 (1.9)
Visceral carcinomatosis on small/large bowel (except rectosigmoid) <sup>d</sup>		
Involved	87 (33.0)	101 (38.3)
Not involved	177 (67.0)	163 (61.7)
NA	0 (0)	0 (0)
Miliary carcinomatosis on the serosa of the small bowel		
Yes	25 (9.5)	38 (14.4)
No	225 (85.2)	224 (84.8)
NA	14 (5.3)	2 (0.8)
Mesenteral retraction of the small bowel		
Yes	56 (21.2)	45 (17.0)
No	202 (76.5)	211 (79.9)
NA	6 (2.3)	8 (3.1)

Data are presented as number (percentage).

NA, not assessable.

<sup>a</sup> "Lesser omentum and/or stomach and/or spleen" is involved when there is carcinomatosis in at least 1 of the 3 sites (lesser omentum, stomach, and spleen); <sup>b</sup> "Parietal peritoneum" is involved when there is carcinomatosis in at least 1 of the 3 sites (right paracolic gutter, left paracolic gutter, abdominal wall); <sup>c</sup> "Diaphragm" is involved when there is carcinomatosis in at least 1 of the diaphragms; <sup>d</sup> "Bowel" is involved when there is visceral carcinomatosis on small and large bowel (except rectosigmoid).

Ultrasound in preoperative staging of advanced ovarian cancer. *Am J Obstet Gynecol* 2022.

assessment of 93 patients with epithelial ovarian cancer. Twelve anatomic regions in the abdomen and in the pelvis were analyzed to assess the presence of spread of disease (rectosigmoid, pelvic peritoneum, major omentum, abdominal peritoneum, bowel, root of mesentery, mesogastrium, hepatic hilum, liver parenchyma, spleen parenchyma, pelvic lymph nodes, and paraaortic lymph nodes). Surgical and pathologic findings were considered as the reference standard. Ultrasound examination proved an overall sensitivity of 70.3%, specificity of 97.8%, and an agreement with surgical findings of  $k=0.69$ . The performance of ultrasound examination was similar to that of CT (sensitivity of 60.1%; specificity of 93.7%;  $k=0.70$ ). In 2022, Fischerova et al published the first prospective study comparing ultrasound, CT, and whole-body diffusion-weighted (WB-DW) MRI in 67 patients with ovarian cancer.<sup>17</sup> First, they demonstrated that ultrasound was not inferior to CT in the evaluation of disease spread ( $P=.002$ ). They also showed that ultrasound and WB-DW-MRI performed better than CT in the identification of overall peritoneal carcinomatosis (areas under the curve, 0.87, 0.86, and 0.77, respectively). For assessment of retroperitoneal lymph-node staging and prediction of nonresectability in the abdomen, all 3 methods performed similarly. In general, ultrasound had higher or identical specificity when compared with WB-DW-MRI and CT at each of the 19 peritoneal (abdominal and pelvic) sites evaluated, but lower or equal sensitivity in the abdomen. Ultrasound had higher accuracy and sensitivity (93% and 100%) than WB-DW-MRI (83% and 75%) and CT (84% and 88%) in the evaluation of rectosigmoid wall infiltration. In contrast, for bowel serosal and mesenteric assessment, ultrasound had the lowest accuracy (70%, 78%, and 79%, respectively) and sensitivity (42%, 65%, and 65%, respectively).

Although these data on the use of ultrasound examination in the staging of ovarian cancer are encouraging, we should underline that these studies were performed by experienced ultrasound

TABLE 3

**Kappa agreement of preoperative ultrasound findings with intraoperative findings at diagnostic laparoscopy in the study population**

Parameter	Cohen's kappa	95% CI		Percentage agreement (%)
Supracolic omentum disease	0.85	0.77	0.92	93.8
Carcinomatosis on the liver	0.73	0.63	0.82	89.0
Lesser omental carcinomatosis and/or carcinomatosis on the lesser curvature of the stomach and/or carcinomatosis on the spleen	0.54	0.42	0.66	77.8
Lesser omental carcinomatosis	0.55	0.41	0.68	81.2
Carcinomatosis on the lesser curvature of the stomach	0.25	0.08	0.42	82.0
Carcinomatosis on the spleen	0.45	0.26	0.63	84.7
Parietal peritoneal involvement	0.63	0.54	0.72	81.8
Parietal peritoneal involvement of the right paracolic gutter	0.64	0.54	0.74	81.9
Parietal peritoneal involvement of the left paracolic gutter	0.65	0.55	0.74	82.2
Parietal peritoneal involvement of the abdominal wall	0.28	0.15	0.49	72.1
Parietal peritoneal involvement on the diaphragms	0.70	0.61	0.79	87.1
Parietal peritoneal involvement of the right diaphragm	0.67	0.57	0.77	85.2
Parietal peritoneal involvement of the left diaphragm	0.42	0.31	0.53	71.6
Carcinomatosis on small/large bowel (except rectosigmoid)	0.90	0.84	0.95	71.6
PIV	0.74	0.66	0.82	87.1
Miliary carcinomatosis on the serosa of the small bowel	0.36	0.19	0.54	86.8
Mesenteral retraction of the small bowel	0.57	0.44	0.69	86.5

CI, confidence interval; PIV, predictive index value.

Ultrasound in preoperative staging of advanced ovarian cancer. *Am J Obstet Gynecol* 2022.

examiners in dedicated settings. Therefore, ultrasound examination may not be proposed to all centers unless examiners receive specific training. At present, CT remains the imaging of choice for the assessment of extension of disease in most centers. Conversely, it must be underlined that an experienced professional is required to interpret not only the images of ultrasound, which is usually considered a user-dependent tool, but also to evaluate the images of other diagnostic methods such as MRI and CT.

Another important issue to consider is that the performance of ultrasound in the assessment of disease spread is lower in obese women. This is to be expected because the assessment of the abdomen is more difficult in these cases.

### Clinical implications

Access to a preoperative diagnostic method able to examine the extension of

disease in the abdomen of patients with ovarian cancer is clinically important. It can allow personalization of treatment, and aid counseling and the choice of the appropriate hospital. It can also allow risk planning related to surgery, including bowel resection and/or upper abdominal surgery, the timetable of the operating room, and the selection of the surgical team and equipment.

### Research implications

This study has proposed strategies for the management of patients with advanced ovarian cancer. For example, ultrasound examination can be an alternative diagnostic tool to CT mainly for those patients allergic to contrast media. Imaging methods (ultrasound examination or CT) can be useful in cases of patients unsuitable for diagnostic surgery because of severe comorbidities or clear evidence of advanced

unresectable disease, and for performing biopsies for quick histologic diagnosis and molecular profiling.

### Strengths and limitations

This study evaluated the performance of ultrasound examination in assessing laparoscopic parameters according to the PIV score. Other strengths of this study are its prospective design, the consecutive inclusion of a large number of patients with suspected advanced ovarian cancer in a third-level gynecologic oncology center, the use of standardized ultrasound<sup>17,22</sup> and laparoscopic methodology for the assessment of tumor spread,<sup>9,10</sup> and the use of a predefined protocol for ultrasound and surgical examinations. A possible limitation of our study is that only 4 experts in gynecologic oncology ultrasound performed the examinations. This decision guaranteed a high level of

**TABLE 4**  
**Performance of ultrasound to assess intraabdominal sites of disease using laparoscopy as the reference in the study population**

US parameter (total=264)	Sensitivity (%) (95% CI)	Specificity (%) (95% CI)	PPV (%) (95% CI)	NPV (%) (95% CI)	Accuracy %	Accuracy							
						AUC	LR+	LR-	TP	FN	FP	TN	TOT
Supracolic omentum disease	97.3 (93.87–99.13)	85.1 (74.96–92.34)	94.3 (90.03–97.12)	92.6 (83.67–97.57)	93.8	0.91	6.5	0.0	182	5	11	63	261
Visceral carcinomatosis on the liver	72.1 (60.93–81.65)	96.5 (92.73–98.74)	90.4 (80.41–96.42)	88.54 (83.17–92.68)	89.1	0.84	21.16	0.28	57	22	6	170	255
Lesser omental carcinomatosis/ visceral carcinomatosis on the lesser curvature of the stomach/ visceral carcinomatosis on the spleen	67.4 (56.48–77.16)	85.8 (78.03–91.68)	78.3 (67.28–87.11)	77.6 (69.28–84.57)	77.8	0.76	4.7	0.4	58	28	16	97	199
Lesser omental carcinomatosis	67.9 (53.68–80.08)	86.8 (79.74–92.13)	67.9 (53.68–80.08)	86.8 (79.74–92.13)	81.2	0.77	5.1	0.3	36	17	17	112	182
Visceral carcinomatosis on the lesser curvature of the stomach	24.3 (11.77–41.20)	95.5 (91.08–98.20)	56.2 (29.88–80.25)	84.3 (78.19–89.35)	82.0	0.59	5.49	0.7	9	28	7	151	195
Visceral carcinomatosis on the spleen	41.9 (24.55–60.92)	95.8 (90.54–98.63)	72.2 (46.52–90.31)	86.4 (79.46–91.78)	84.7	0.68	10.1	0.61	13	18	5	115	151
Parietal peritoneal involvement	93.1 (87.36–96.81)	69.6 (60.70–77.67)	76.7 (69.38–83.06)	90.43 (82.60–95.53)	81.8	0.81	3.1	0.09	122	9	37	85	253
Parietal peritoneal involvement of the right paracolic gutter	86.6 (78.87–92.31)	77.5 (68.98–84.62)	78.2 (69.92–85.13)	86.1 (78.13–92.01)	81.9	0.82	3.85	0.17	97	15	27	93	232
Parietal peritoneal involvement of the left paracolic gutter	90.6 (83.48–95.43)	74.5 (65.74–82.14)	76.3 (68.03–83.46)	89.8 (82.03–95.00)	82.2	0.82	3.56	0.12	97	10	30	88	225
Parietal peritoneal involvement of the abdominal wall	32.9 (22.75–44.40)	91.77 (86.34–95.55)	66.6 (49.78–80.91)	73.2 (66.49–79.26)	71.73	0.62	3.71	0.73	26	53	14	144	237
Parietal peritoneal involvement of the diaphragms	89.7 (84.32–93.83)	81.2 (70.97–89.11)	91.3 (86.10–95.07)	78.3 (67.91–86.61)	87.1	0.81	4.7	0.1	158	18	15	65	256
Parietal peritoneal involvement of the right diaphragm	85.8 (79.73–90.74)	83.7 (73.82–91.05)	91.8 (86.42–95.57)	73.6 (63.35–82.31)	85.2	0.84	5.3	0.2	146	24	13	67	250
Parietal peritoneal involvement of the left diaphragm	64.7 (54.83–73.84)	77.1 (68.95–83.98)	69.4 (59.26–78.30)	73.2 (64.99–80.37)	71.6	0.70	2.5	0.4	68	37	30	101	236
Visceral carcinomatosis on small/ large bowel (except rectosigmoid)	95.2 (88.25–98.69)	95.7 (91.35–98.26)	91.9 (84.12–96.70)	97.5 (93.72–99.31)	95.5	0.95	22.2	0.05	80	4	7	156	247
PIV	83.8 (76.37–89.71)	90.3 (83.98–94.73)	89.34 (82.47–94.20)	85.21 (78.29–90.61)	87.1	0.87	8.6	0.17	109	21	13	121	264
Miliary carcinomatosis on small bowel serosa	38.2 (22.17–56.44)	94.4 (90.50–97.10)	52 (31.31–72.20)	90.6 (86.09–94.13)	86.8	0.66	6.88	0.65	13	21	12	204	250
Mesenteral retraction of the small bowel	71.1 (55.69–83.63)	89.8 (84.91–93.61)	60.3 (46.00–73.55)	93.4 (89.09–96.48)	86.5	0.80	7.01	0.32	32	13	21	186	252

Data are presented as percentage.

AUC, area under the curve; CI, confidence interval; FN, false negative; FP, false positive; LR-, negative likelihood ratio; LR+, positive likelihood ratio; NPV, negative predictive value; PIV, predictive index value; PPV, positive predictive value; TN, true negative; TOT, total number; TP, true positive; US, ultrasound.

Ultrasound in preoperative staging of advanced ovarian cancer. *Am J Obstet Gynecol* 2022.

standardization and high quality of data, but the generalizability of our results could be questioned. Thus far, we have no data about interobserver agreement in evaluating ovarian cancer spread, nor about learning curves in this specific area. However, these were not the aims of the present study and could be studied later.

Another limitation of the study could be the use of laparoscopy as the reference standard rather than laparotomy, which allows evaluation of some areas that are difficult to visualize at laparoscopy (ie, posterior surface of the liver, hepatic hilum, etc.). Conversely, laparoscopy has been shown to be an accurate clinical tool, avoiding unnecessary laparotomies with a very low number of patients incorrectly deprived of laparotomic cytoreduction.

## Conclusions

The results of ultrasound and laparoscopy in the assessment of intra-abdominal tumor spread were in substantial agreement for almost all the parameters. Ultrasound examination can play a useful role in the preoperative management of patients with ovarian cancer when used in dedicated referral centers.

## References

- Sung H, Ferlay J, Siegel RL, et al. Global cancer statistics 2020: GLOBOCAN estimates of incidence and mortality worldwide for 36 cancers in 185 countries. *CA Cancer J Clin* 2021;71:209–49.
- Webb PM, Jordan SJ. Epidemiology of epithelial ovarian cancer. *Best Pract Res Clin Obstet Gynaecol* 2017;41:3–14.
- Bristow RE, Tomacruz RS, Armstrong DK, Trimble EL, Montz FJ. Survival effect of maximal cytoreductive surgery for advanced ovarian carcinoma during the platinum era: a meta-analysis. *J Clin Oncol* 2002;20:1248–59.
- du Bois A, Reuss A, Pujade-Lauraine E, Harter P, Ray-Coquard I, Pfisterer J. Role of surgical outcome as prognostic factor in advanced epithelial ovarian cancer: a combined exploratory analysis of 3 prospectively randomized phase 3 multicenter trials: by the Arbeitsgemeinschaft Gynaekologische Onkologie Studiengruppe Ovarialkarzinom (AGO-OVAR) and the Groupe d'Investigateurs Nationaux pour les Etudes des Cancers de l'ovaire (GINECO). *Cancer* 2009;115:1234–44.
- Chi DS, Eisenhauer EL, Lang J, et al. What is the optimal goal of primary cytoreductive surgery for bulky stage IIIc epithelial ovarian carcinoma (EOC)? *Gynecol Oncol* 2006;103:559–64.
- Vergote I, Tropé CG, Amant F, et al. Neoadjuvant chemotherapy or primary surgery in stage IIIc or IV ovarian cancer. *N Engl J Med* 2010;363:943–53.
- Kehoe S, Hook J, Nankivell M, et al. Primary chemotherapy versus primary surgery for newly diagnosed advanced ovarian cancer (CHORUS): an open-label, randomised, controlled, non-inferiority trial. *Lancet* 2015;386:249–57.
- Gómez-Hidalgo NR, Martínez-Cannon BA, Nick AM, et al. Predictors of optimal cytoreduction in patients with newly diagnosed advanced-stage epithelial ovarian cancer: time to incorporate laparoscopic assessment into the standard of care. *Gynecol Oncol* 2015;137:553–8.
- Fagotti A, Ferrandina G, Fanfani F, et al. A laparoscopy-based score to predict surgical outcome in patients with advanced ovarian carcinoma: a pilot study. *Ann Surg Oncol* 2006;13:1156–61.
- Fagotti A, Ferrandina G, Fanfani F, et al. Prospective validation of a laparoscopic predictive model for optimal cytoreduction in advanced ovarian carcinoma. *Am J Obstet Gynecol* 2008;199:642.e1–6.
- Petrillo M, Vizzielli G, Fanfani F, et al. Definition of a dynamic laparoscopic model for the prediction of incomplete cytoreduction in advanced epithelial ovarian cancer: proof of a concept. *Gynecol Oncol* 2015;139:5–9.
- Timmerman D, Planchamp F, Bourne T, et al. ESGO/ISUOG/IOTA/ESGE Consensus Statement on pre-operative diagnosis of ovarian tumors. *Int J Gynecol Cancer* 2021;31:961–82.
- Testa AC, Ludovisi M, Mascilini F, et al. Ultrasound evaluation of intra-abdominal sites of disease to predict likelihood of suboptimal cytoreduction in advanced ovarian cancer: a prospective study. *Ultrasound Obstet Gynecol* 2012;39:99–105.
- Fischerova D, Zikan M, Semeradova I, et al. Ultrasound in preoperative assessment of pelvic and abdominal spread in patients with ovarian cancer: a prospective study. *Ultrasound Obstet Gynecol* 2017;49:263–74.
- Weinberger V, Fischerova D, Semeradova I, et al. Prospective evaluation of ultrasound accuracy in the detection of pelvic carcinomatosis in patients with ovarian cancer. *Ultrasound Med Biol* 2016;42:2196–202.
- Tempany CM, Zou KH, Silverman SG, Brown DL, Kurtz AB, McNeil BJ. Staging of advanced ovarian cancer: comparison of imaging modalities—report from the Radiological Diagnostic Oncology Group. *Radiology* 2000;215:761–7.
- Fischerova D, Pinto P, Burgetova A, et al. Preoperative staging of advanced ovarian cancer: comparison between ultrasound, CT and whole-body diffusion-weighted MRI (ISAAC study). *Ultrasound Obstet Gynecol* 2022;59:248–62.
- Moruzzi MC, Bolomini G, Moro F, et al. Diagnostic performance of ultrasound in assessing the extension of the disease in patients with suspicion of malignant ovarian tumor: correlation between ultrasound parameters and Fagotti's score. *Int J Gynecol Cancer* 2021;31:279–85.
- Timmerman D, Valentin L, Bourne TH, et al. Terms, definitions and measurements to describe the sonographic features of adnexal tumors: a consensus opinion from the International Ovarian Tumor Analysis (IOTA) Group. *Ultrasound Obstet Gynecol* 2000;16:500–5.
- Landis JR, Koch GG. Rho measurement of observer agreement for categorical data. *Biometrics* 1977;33:159–74.
- Alcázar JL, Caparros M, Arraiza M, et al. Pre-operative assessment of intra-abdominal disease spread in epithelial ovarian cancer: a comparative study between ultrasound and computed tomography. *Int J Gynecol Cancer* 2019;29:227–33.
- Fischerova D. Ultrasound scanning of the pelvis and abdomen for staging of gynecological tumors: a review. *Ultrasound Obstet Gynecol* 2011;38:246–66.

## Author and article information

From the Dipartimento Scienze della Salute della Donna, del Bambino e di Sanità Pubblica, Fondazione Policlinico Universitario Agostino Gemelli, Istituto di Ricovero e Cura a Carattere Scientifico, Rome, Italy (Drs Moruzzi, Bolomini, Esposito, Mascilini, Ciccarone, Quagliozzi, Giudice, Beneduce, Ficarelli, Scambia, Fagotti, Testa, and Moro); Direzione Scientifica, Fondazione Policlinico Universitario Agostino Gemelli, Istituto di Ricovero e Cura a Carattere Scientifico, Rome, Italy (Dr Moroni); and Università Cattolica del Sacro Cuore, Istituto di Clinica Ostetrica e Ginecologica, Rome, Italy (Drs Scambia, Fagotti, and Testa).

Received Dec. 24, 2021; revised May 4, 2022; accepted May 10, 2022.

The authors report no conflict of interest.

This study did not receive any financial support.

Corresponding author: Francesca Moro, MD, PhD. morofrancy@gmail.com

**SUPPLEMENTAL FIGURE 1**  
**Clinical Report Form for ultrasound evaluation**

**ULTRASOUND EVALUATION**

**ABSOLUTE CRITERIA OF UNRESECTABILITY:**

**Miliatic carcinomatosis on the serosa of the small bowel**  
*Please write yes only in case of diffuse small bowel carcinomatosis*



YES  NO  NA

**Mesenteral retraction of the small bowel\***  
*Please write yes in case of the evidences of indirect signs: subjective evaluation of 'fixity' or 'hypomobility' of bowel loops towards mesenteric root, with 'cauliflower' appearance*



YES  NO  NA

**ULTRASOUND PARAMETERS FOR PI EVALUATION:**

In each section, a value of 2 will be given in presence of one or more positive parameters.

**1. Supracolic omentum disease**

*Please write yes when a thickened layer is seen; in case of detection of only discrete nodule(s) please write no*

Sheet-like (mm.....)  
*Please, measure the largest thickness*



YES  NO  NA

0 2

**2. Visceral carcinomatosis on the liver**

Sheet-like of Glisson's capsule (mm.....)  
*Please, measure the largest diameter*



YES  NO  NA

Nodule (mm.....in.....)  
*Please, measure the largest diameter in mm and indicate the corresponding liver segment*



YES  NO  NA

0 2

**4. Involvement of the peritoneum:**

a. Parietal peritoneal involvement of the right paracolic gutter  
Dimension (mm.....)



YES  NO  NA

b. Parietal peritoneal involvement of the left paracolic gutter  
Dimension (mm.....)



YES  NO  NA

c. Parietal peritoneal involvement of anterior abdominal wall  
Dimension (mm.....)

YES  NO  NA

YES  NO  NA

0 2

**3. Involvement of one of the following structures:**

a. Lesser omental carcinomatosis

YES  NO  NA

Dimension (mm.....)



b. Visceral carcinomatosis on the lesser curvature of stomach  
Dimension (mm.....)

YES  NO  NA



c. Visceral carcinomatosis on the spleen  
Dimension (mm.....)

YES  NO  NA



*Please write yes in case of one or more nodules or sheet-like; please measure the largest diameter in mm.*

0 2

**5. Involvement of the diaphragms:**

a. Parietal peritoneal involvement of the right diaphragm  
Dimension (mm.....)



YES  NO  NA

b. Parietal peritoneal involvement of the left diaphragm  
Dimension (mm.....)



YES  NO  NA

*Please write yes only in case of confluent nodules or sheet-like; please write the largest diameter*

0 2

*\* In case of isolated nodule(s), please write yes only if bilateral*

6. Visceral carcinomatosis on small/large bowel (except rectosigmoid)  
Dimension (mm.....)

YES  NO  NA



0 2

*\* Thickening or confluent nodules of the large/small bowel wall that may request resection because of wall's infiltration (excluding recto-sigmoid involvement)*

**TOTAL ULTRASOUND PI:**


0 2 4 6 8 10 12

**SUPPLEMENTAL FIGURE 2**  
**Clinical Report Form for laparoscopic evaluation**


**SURGICAL EVALUATION**

**ABSOLUTE CRITERIA OF UNRESECTABILITY:**

**Miliaric carcinomatosis on the serosa of the small bowel**  YES  NO  NA  
*Please write yes only in case of diffuse small bowel carcinomatosis*




**Mesenteral retraction of the small bowel**  YES  NO  NA





**SURGICAL PARAMETERS FOR PLEVALUATION:**  
 In each section, a value of 2 will be given in presence of one or more positive parameters.

**1. Omental disease**  
*Please write yes when a thickened layer is seen; in case of detection of only discrete nodule(s) please write no*


- Sheet-like  YES  NO  NA  



**2. Liver surface (nodule or diffuse carcinomatosis ≥ 2 cm)**


- Sheet-like of Glisson's capsule  YES  NO  NA  


- Nodule  YES  NO  NA  



**3. Involvement of one of the following structure:**


a. Lesser omentum (hepatogastric ligament) and/or  YES  NO  NA  


b. Stomach (small curvature) and/or  YES  NO  NA  



c. Spleen  YES  NO  NA  
    
*Please write yes only in case of confluent nodules or sheet-like.*


**4. Involvement of the peritoneum:**


a. Parietal peritoneum right paracolic gutter  YES  NO  NA  


b. Parietal peritoneum left paracolic gutter  YES  NO  NA  


c. Peritoneal abdominal wall  YES  NO  NA  
 YES  NO  NA

**5. Right diaphragmatic carcinomatosis\***  YES  NO  NA  


**Left diaphragmatic carcinomatosis\***  YES  NO  NA  
  
*Please write yes only in case of confluent nodules or sheet-like;*  
*\* In case of isolated nodule(s), please write yes only if bilateral*

**6. Bowel disease\***  YES  NO  NA  
    
*\* Thickening or confluent nodules of the large/small bowel wall that may request resection because of wall's infiltration (excluding recto-sigmoid involvement)*

**TOTAL SURGICAL PI:**

Moruzzi. Ultrasound in preoperative staging of advanced ovarian cancer. Am J Obstet Gynecol 2022.

**SUPPLEMENTAL TABLE 1**  
**Ultrasound findings of the study population**

Characteristic	All (n=264)
Ascites	202 (76.5)
Tumor masses side	
Monolateral	23/253 (9.0)
Middle	57/253 (22.5)
Bilateral	173/253 (68.3)
No adnexal masses	11 (4.2)
Largest diameter of lesion (mm)	70.5 (18–290)
Type of tumor	
Unilocular	3/253 (1.2)
Unilocular-solid	5/253 (1.9)
Multilocular	0/253 (0)
Multilocular-solid	60/253 (23.7)
Solid	185/253 (73.1)
Number of locules in multilocular-solid masses	
<10	28/60 (46.6)
≥10	32/60 (53.3)
Echogenicity of cyst fluid in tumors not classified as solid	
Anechoic	38/68 (55.9)
Low level	26/68 (38.2)
Ground glass	4/68 (5.9)
Hemorrhagic	0/68 (0)
Mixed	0/68 (0)
Presence of papillary projection(s)	16/253 (6.3)
Ovarian crescent sign	
Yes	1/253 (0.4)
No	251/253 (99.2)
Uncertain	1/253 (0.4)
Color score	
1	20/253 (7.9)
2	27/253 (10.7)
3	146/253 (57.7)
4	60/253 (23.7)

*Ultrasound in preoperative staging of advanced ovarian cancer. Am J Obstet Gynecol 2022.*

SUPPLEMENTAL TABLE 2

## Agreement between ultrasound and laparoscopy, and performance of ultrasound to assess intraabdominal sites of disease using laparoscopy as the reference in the subset of obese women (body mass index&gt;30)

US parameter (total=42)	Cohen's kappa (95% CI)	Sensitivity (%) (95% CI)	Specificity (%) (95% CI)	PPV (%) (95% CI)	NPV (%) (95% CI)	Accuracy	AUC	LR+	LR-	TP	FN	FP	TN	TOT
Supracolic omentum disease	0.68 (0.42–0.93)	96.55 (82.24–99.91)	66.67 (34.89–90.08)	87.50 (71.01–96.49)	88.89 (51.75–99.72)	87.8	0.81	2.89	0.10	28	1	4	8	41
Visceral carcinomatosis on the liver	0.53 (0.22–0.85)	50.00 (18.71–81.29)	96.67 (82.78–99.92)	83.33 (35.88–99.58)	85.29 (68.94–95.05)	85.0	0.73	15.00	0.50	5	5	1	29	40
Lesser omental carcinomatosis/ visceral carcinomatosis on the lesser curvature of the stomach/ visceral carcinomatosis on the spleen	0.55 (0.21–0.88)	60.00 (26.24–87.84)	92.86 (66.13–99.82)	85.71 (42.13–99.64)	76.47 (50.10–93.19)	79.17	0.76	8.40	0.40	6	4	1	13	24
Lesser omental carcinomatosis	0.50 (0.14–0.86)	55.56 (21.20–86.30)	92.31 (63.97–99.81)	83.33 (35.88–99.58)	75.00 (47.62–92.73)	77.27	0.73	7.20	0.48	5	4	1	12	22
Visceral carcinomatosis on the lesser curvature of the stomach	NA	0.00 (0.00–60.00)	100 (82.35–100.00)	NA	82.61 (61.22–95.05)	82.61	0.5	NA	89.86	0	4	0	19	23
Visceral carcinomatosis on the spleen	0.64 (0.00–0.99)	50.00 (1.26–98.74)	100 (81.47–100.00)	100.00 (2.50–100.00)	94.74 (73.97–99.87)	95.0	0.47	18.00	0.50	1	1	0	18	20
Parietal peritoneal involvement	0.52 (0.26–0.79)	86.96 (66.41–97.22)	64.71 (38.33–85.79)	76.92 (56.35–91.03)	78.57 (49.20–95.34)	77.5	0.75	2.40	0.20	20	3	6	11	40
Parietal peritoneal involvement of the right paracolic gutter	0.611 (0.35–0.86)	77.78 (52.36–93.59)	83.33 (58.58–96.42)	82.35 (56.57–96.20)	78.95 (54.43–93.95)	80.56	0.80	4.60	0.20	14	4	3	15	36
Parietal peritoneal involvement of the left paracolic gutter	0.57 (0.29–0.84)	89.47 (66.86–98.70)	66.67 (38.38–88.18)	77.27 (54.63–92.18)	83.33 (51.59–97.91)	79.41	0.78	2.70	0.20	17	2	5	10	34
Parietal peritoneal involvement of the abdominal wall	0.30 (0.00–0.63)	36.36 (10.93–69.21)	90.48 (69.62–98.83)	66.67 (22.28–95.67)	73.08 (52.21–88.43)	71.88	0.63	3.80	0.70	4	7	2	19	32
Parietal peritoneal involvement of the diaphragms	0.83 (0.66–0.99)	88.89 (70.84–97.65)	100.00 (75.29–100.00)	100.00 (85.75–100.00)	81.25 (54.35–95.95)	92.50	0.94	23.20	0.20	24	3	0	13	40
Parietal peritoneal involvement of the right diaphragm	0.83 (0.66–0.99)	88.89 (70.84–97.65)	100.00 (75.29–100.00)	100.00 (85.75–100.00)	81.25 (54.35–95.95)	92.50	0.94	23.20	0.20	24	3	0	13	40
Parietal peritoneal involvement of the left diaphragm	0.26 (0.00–0.55)	44.44 (21.53–69.24)	80.95 (58.09–94.55)	66.67 (34.89–90.08)	62.96 (42.37–80.60)	64.10	0.62	2.30	0.70	8	10	4	17	39
Visceral carcinomatosis on small/ large bowel (except rectosigmoid)	0.892 (0.745–0.999)	92.86 (66.13–99.82)	96.30 (81.03–99.91)	92.86 (66.13–99.82)	96.30 (81.03–99.91)	95.12	0.94	25.10	0.10	13	1	1	26	41
PIV	0.671 (0.461–0.881)	68.18 (45.13–86.14)	100 (83.16–100.00)	100 (78.20–100.00)	74.07 (78.20–100.00)	83.33	0.84	27.27	0.32	15	7	0	20	42

Ultrasound in preoperative staging of advanced ovarian cancer. Am J Obstet Gynecol 2022.

(continued)

## SUPPLEMENTAL TABLE 2

**Agreement between ultrasound and laparoscopy, and performance of ultrasound to assess intraabdominal sites of disease using laparoscopy as the reference in the subset of obese women (body mass index>30) (continued)**

US parameter (total=42)	Cohen's kappa (95% CI)	Sensitivity (%) (95% CI)	Specificity (%) (95% CI)	PPV (%) (95% CI)	NPV (%) (95% CI)	Accuracy	AUC	LR+	LR-	TP	FN	FP	TN	TOT
Miliary carcinomatosis on small bowel serosa	0.18 (0.00–0.50)	12.50 (0.32–52.65)	100.00 (89.11–100.00)	100.00 (2.50–100.00)	82.05 (66.47–92.46)	82.50	0.56	8.00	0.87	1	7	0	32	40
Mesenteral retraction of the small bowel	0.72 (0.43–0.99)	83.33 (35.88–99.58)	94.29 (80.84–99.30)	71.43 (29.04–96.33)	97.06 (84.67–99.93)	92.68	0.88	14.58	0.17	5	1	2	33	41

Data are presented as percentage.

AUC, area under the curve; CI, confidence interval; FN, false negative; FP, false positive; LR-, negative likelihood ratio; LR+, positive likelihood ratio; NA, not assessable; NPV, negative predictive value; PIV, predictive index value; PPV, positive predictive value; TN, true negative; TOT, total number; TP, true positive; US, ultrasound.

Ultrasound in preoperative staging of advanced ovarian cancer. *Am J Obstet Gynecol* 2022.

SUPPLEMENTAL TABLE 3

**Agreement between ultrasound and laparoscopy, and performance of ultrasound to assess intraabdominal sites of disease using laparoscopy as the reference in the subset of women with primary advanced ovarian cancer at histology**

US parameter (total=210)	Cohen's kappa (95% CI)	Sensitivity (%) (95% CI)	Specificity (%) (95% CI)	PPV (%) (95% CI)	NPV (%) (95% CI)	Accuracy (%)	AUC	LR+	LR-	TP	FN	FP	TN	TOT
Supracolic omentum disease	0.82 (0.73–0.92)	97.66 (94.12–99.36)	83.33 (67.19–93.63)	96.53 (92.60–98.72)	88.24 (72.55–96.70)	95.17	0.90	5.86	0.03	167	4	6	30	207
Visceral carcinomatosis on the liver	0.70 (0.60–0.80)	72.22 (60.41–82.14)	95.35 (90.15–98.27)	89.66 (78.83–96.11)	86.01 (79.23–91.24)	87.06	0.83	15.53	0.29	52	20	6	123	201
Lesser omental carcinomatosis/visceral carcinomatosis on the lesser curvature of the stomach/visceral carcinomatosis on the spleen	0.49 (0.36–0.63)	68.75 (57.41–78.65)	81.08 (70.30–89.259)	79.71 (68.31–88.44)	70.59 (59.71–79.98)	74.68	0.74	3.63	0.39	55	25	14	60	154
Lesser omental carcinomatosis	0.56 (0.42–0.71)	71.43 (56.74–83.42)	85.23 (76.06–91.89)	72.92 (58.15–84.72)	84.27 (75.02–91.12)	80.29	0.78	4.84	0.34	35	14	13	75	137
Visceral carcinomatosis on the lesser curvature of the stomach	0.21 (0.04–0.39)	23.53 (10.75–41.17)	94.02 (88.06–97.56)	53.33 (26.59–78.73)	80.88 (73.26–87.12)	78.15	0.58	3.93	0.81	8	26	7	110	151
Visceral carcinomatosis on the spleen	0.45 (0.25–0.64)	46.43 (27.51–66.13)	93.59 (85.67–97.89)	72.22 (46.52–90.31)	82.95 (73.45–90.13)	81.13	0.70	7.24	0.57	13	15	5	73	106
Parietal peritoneal involvement	0.60 (0.49–0.71)	92.31 (85.90–96.42)	66.27 (55.05–76.28)	79.41 (71.64–85.86)	85.94 (74.98–93.36)	81.50	0.79	2.74	0.12	108	9	28	55	200
Parietal peritoneal involvement of the right paracolic gutter	0.57 (0.45–0.69)	86 (77.63–92.13)	70.73 (59.65–80.26)	78.18 (69.30–85.49)	80.56 (69.53–88.94)	79.12	0.78	2.94	0.20	86	14	24	58	182
Parietal peritoneal involvement of the left paracolic gutter	0.62 (0.5–0.73)	89.58 (81.68–94.89)	71.95 (60.94–81.32)	78.9 (70.04–86.13)	85.51 (74.96–92.83)	81.46	0.80	3.19	0.14	86	10	23	59	178
Parietal peritoneal involvement of the abdominal wall	0.21 (0.08–0.35)	30.43 (19.92–42.69)	88.89 (81.75–93.95)	61.76 (43.56–77.83)	68.42 (60.40–75.71)	67.20	0.59	2.74	0.78	21	48	13	104	186
Parietal peritoneal involvement of the diaphragms	0.56 (0.42–0.7)	89.57 (83.83–93.81)	70 (53.47–83.44)	92.41 (87.11–96.01)	62.22 (46.54–76.23)	85.71	0.79	2.99	0.15	146	17	12	28	203
Parietal peritoneal involvement of the right diaphragm	0.53 (0.4–0.67)	85.35 (78.83–90.48)	75 (58.80–87.31)	93.06 (87.60–96.62)	56.6 (42.28–70.169)	83.25	0.80	3.41	0.20	134	23	10	30	197

Ultrasound in preoperative staging of advanced ovarian cancer. Am J Obstet Gynecol 2022.

(continued)

## SUPPLEMENTAL TABLE 3

**Agreement between ultrasound and laparoscopy, and performance of ultrasound to assess intraabdominal sites of disease using laparoscopy as the reference in the subset of women with primary advanced ovarian cancer at histology** (continued)

US parameter (total=210)	Cohen's kappa (95% CI)	Sensitivity (%) (95% CI)	Specificity (%) (95% CI)	PPV (%) (95% CI)	NPV (%) (95% CI)	Accuracy (%)	AUC	LR+	LR-	TP	FN	FP	TN	TOT
Parietal peritoneal involvement of the left diaphragm	0.32 (0.18–0.46)	65.63 (55.23–75.02)	67.05 (56.21–76.70)	68.48 (57.96–77.77)	64.13 (53.46–73.87)	66.30	0.66	1.99	0.51	63	33	29	59	184
Visceral carcinomatosis on small/large bowel (except rectosigmoid)	0.88 (0.81–0.94)	94.74 (87.07–98.55)	94.12 (88.26–97.60)	91.14 (82.59–96.36)	96.55 (91.41–99.05)	94.36	0.94	16.11	0.06	72	4	7	112	195
PIV	0.68 (0.58–0.78)	82.93 (75.09–89.11)	86.21 (77.15–92.66)	89.47 (82.33–94.44)	78.13 (68.53–85.92)	84.29	0.84	6.01	0.20	102	21	12	75	210
Miliary carcinomatosis on small bowel serosa	0.35 (0.17–0.53)	40 (22.66–59.40)	92.77 (87.71–96.21)	50 (29.12–70.88)	89.53 (83.97–93.68)	84.69	0.66	5.53	0.65	12	18	12	154	196
Mesenteral retraction of the small bowel	0.55 (0.41–0.69)	71.79 (55.13–85.00)	88.13 (82.08–92.70)	59.57 (44.27–73.63)	92.76 (87.42–96.33)	84.92	0.80	6.05	0.32	28	11	19	141	199

Data are presented as percentage.

AUC, area under the curve; CI, confidence interval; FN, false negative; FP, false positive; LR-, negative likelihood ratio; LR+, positive likelihood ratio; NPV, negative predictive value; PIV, predictive index value; PPV, positive predictive value; TN, true negative; TOT, total number; TP, true positive; US, ultrasound.

Ultrasound in preoperative staging of advanced ovarian cancer. Am J Obstet Gynecol 2022.

SUPPLEMENTAL TABLE 4

## Agreement between ultrasound and laparotomy, and performance of ultrasound using laparotomy as the reference standard in the subset of women who underwent laparotomic cytoreduction

US parameter (total=148)	Cohen's kappa (95% CI)	Sensitivity (%) (95% CI)	Specificity (%) (95% CI)	PPV (%) (95% CI)	NPV (%) (95% CI)	Accuracy (%)	AUC	LR+	LR-	TP	FN	FP	TN	TOT
Supracolic omentum disease	0.80 (0.7–0.9)	94.81 (87.23–98.57)	85.29 (74.61–92.72)	87.95 (78.96–94.08)	93.55 (84.30–98.21)	90.34	0.90	6.45	0.06	73	4	10	58	145
Visceral carcinomatosis on the liver	0.75 (0.6–0.9)	77.27 (54.63–92.18)	96.75 (91.88–99.11)	80.95 (58.09–94.55)	95.97 (90.84–98.68)	93.79	0.87	23.76	0.23	17	5	4	119	145
Lesser omental carcinomatosis/visceral carcinomatosis on the lesser curvature of the stomach/visceral carcinomatosis on the spleen	0.49 (0.3–0.68)	61.54 (40.57–79.77)	88.30 (80.03–94.01)	59.26 (38.80–77.61)	89.25 (81.11–94.72)	82.50	0.75	5.26	0.44	16	10	11	83	120
Lesser omental carcinomatosis	0.59 (0.35–0.83)	80.00 (44.39–97.48)	93.20 (86.50–97.22)	53.33 (26.59–78.73)	97.96 (92.82–99.75)	92.04	0.87	11.77	0.21	8	2	7	96	113
Visceral carcinomatosis on the lesser curvature of the stomach	–0.0 (–0.05 to 0)	00.00 (00.00–60.24)	97.37 (92.50–99.45)	00.00 (00.00–70.76)	96.52 (91.33–99.04)	94.07	0.49	0.00	1.03	0	4	3	111	118
Visceral carcinomatosis on the spleen	0.30 (0.05–0.55)	31.25 (11.02–58.66)	94.57 (87.77–98.21)	50.00 (18.71–81.29)	88.78 (80.80–94.26)	85.19	0.63	5.75	0.73	5	11	5	87	108
Parietal peritoneal involvement	0.50 (0.36–0.63)	87.80 (73.80–95.92)	71.29 (61.43–79.85)	55.38 (42.53–67.73)	93.51 (85.49–97.86)	76.06	0.80	3.06	0.17	36	5	29	72	142
Parietal peritoneal involvement of the right paracolic gutter	0.50 (0.34–0.65)	75.68 (58.80–88.23)	79.38 (69.97–86.93)	58.33 (43.21–72.39)	89.53 (81.06–95.10)	78.36	0.78	3.67	0.31	28	9	20	77	134
Parietal peritoneal involvement of the left paracolic gutter	0.51 (0.36–0.66)	84.85 (68.10–94.89)	76.29 (66.58–84.34)	54.90 (40.34–68.87)	93.67 (85.84–97.91)	78.46	0.81	3.58	0.20	28	5	23	74	130
Parietal peritoneal involvement of the abdominal wall	0.25 (0.03–0.46)	33.33 (14.59–56.97)	90.35 (83.39–95.08)	38.89 (17.30–64.25)	88.03 (80.74–93.30)	81.48	0.62	3.45	0.74	7	14	11	103	135
Parietal peritoneal involvement of the diaphragms	0.66 (0.54–0.78)	82.19 (71.47–90.16)	84.29 (73.62–91.89)	84.5 (73.97–92.00)	81.94 (71.11–90.02)	83.22	0.83	5.23	0.21	60	13	11	59	143
Parietal peritoneal involvement of the right diaphragm	0.60 (0.47–0.73)	75.71 (63.99–85.17)	84.72 (74.31–92.12)	82.81 (71.32–91.10)	78.21 (67.41–86.76)	80.28	0.80	4.96	0.29	53	17	11	61	142
Parietal peritoneal involvement of the left diaphragm	0.43 (0.26–0.6)	66.67 (46.04–83.48)	82.88 (74.57–83.48)	48.65 (31.92–65.60)	91.09 (83.76–95.84)	79.71	0.75	3.89	0.40	18	9	19	92	138
Visceral carcinomatosis on small/large bowel (except rectosigmoid)	0.81 (0.66–0.95)	100.00 (78.20–100.00)	95.42 (90.30–98.30)	71.43 (47.82–88.72)	100.00 (97.09–100.00)	95.89	0.98	21.83	0.00	15	0	6	125	146
PIV	0.63 (0.47–0.79)	74.07 (53.72–88.89)	91.74 (85.33–95.97)	66.67 (47.19–82.71)	94.07 (88.16–97.58)	88.51	0.83	8.96	0.28	20	7	10	111	148

Ultrasound in preoperative staging of advanced ovarian cancer. Am J Obstet Gynecol 2022.

(continued)

## SUPPLEMENTAL TABLE 4

**Agreement between ultrasound and laparotomy, and performance of ultrasound using laparotomy as the reference standard in the subset of women who underwent laparotomic cytoreduction** (continued)

US parameter (total=148)	Cohen's kappa (95% CI)	Sensitivity (%) (95% CI)	Specificity (%) (95% CI)	PPV (%) (95% CI)	NPV (%) (95% CI)	Accuracy (%)	AUC	LR+	LR-	TP	FN	FP	TN	TOT
Miliary carcinomatosis on small bowel serosa	-0.01 (-0.02 to 0)	00.00 (00.00 -97.50)	97.16 (92.90 -99.22)	00.00 (00.00 -60.24)	99.28 (96.03 -99.98)	96.48	0.49	0.00	1.03	0	1	4	137	142
Mesenteral retraction of the small bowel	0.16 (-0.13 to 0.46)	50.00 (1.26 -98.74)	94.37 (89.20 -97.54)	11.11 (0.28 -48.25)	99.26 (95.94 -99.98)	93.75	0.72	8.88	0.53	1	1	8	134	144

Data are presented as percentage.

AUC, area under the curve; CI, confidence interval; FN, false negative; FP, false positive; LR-, negative likelihood ratio; LR+, positive likelihood ratio; NPV, negative predictive value; PIV, predictive index value; PPV, positive predictive value; TN, true negative; TOT, total number; TP, true positive; US, ultrasound.

Ultrasound in preoperative staging of advanced ovarian cancer. *Am J Obstet Gynecol* 2022.