


A second case report of medulloblastoma in a patient carrying biallelic pathogenic *MUTYH* germline variants

Selene Cipri¹ | Giada Del Baldo^{1,2} | Andrea Carai³ | Antonella Cacchione¹ |
Emanuele Agolini⁴ | Antonio Novelli⁴ | Sabrina Rossi⁵  |
Giovanna Stefania Colafati^{6,7} | Luigi Boccutto⁸ | Angela Mastronuzzi¹

¹Department of Hematology/Oncology, Cell Therapy, Gene Therapies and Hemopoietic Transplant, Bambino Gesù Children's Hospital, IRCCS, Rome, Italy

²Department of Experimental Medicine, Sapienza University of Rome, Rome, Italy

³Department of Neurosciences, Neurosurgery Unit, Bambino Gesù Children's Hospital, IRCCS, Rome, Italy

⁴Laboratory of Medical Genetics, Bambino Gesù Children's Hospital, IRCCS, Rome, Italy

⁵Pathology Unit, Department of Laboratories, Bambino Gesù Children's Hospital, IRCCS, Rome, Italy

⁶Imaging Department, Bambino Gesù Children's Hospital, IRCCS, Rome, Italy

⁷Department of Neuroscience, Imaging and Clinical Sciences (DNISC), University "Gabriele D'Annunzio" of Chieti-Pescara, Chieti, Italy

⁸Healthcare Genetics Program, School of Nursing, College of Behavioral, Social and Health Sciences, Clemson University, Clemson, South Carolina, USA

Correspondence

Angela Mastronuzzi, Department of Hematology/Oncology, Cell Therapy, Gene Therapies and Hemopoietic Transplant, Bambino Gesù Children's Hospital, IRCCS, Rome, Italy.

Email: angela.mastronuzzi@opbg.net

Funding information

European Reference Network Genetic Tumour Risk Syndromes (ERN GENTURIS); 'Il Laboratorio di Chiara' Foundation

KEYWORDS: cancer predisposition syndrome, medulloblastoma, *MUTYH*, paediatric brain tumours

The *MutY DNA Glycosylase (MUTYH)* gene is a primary component of the base excision repair (BER) pathway.¹ It plays a role in fixing DNA damage caused by environmental factors, particularly in G:C to T:A transversions that result from guanine oxidation.^{1,2} Biallelic germline pathogenic variants in *MUTYH* have been associated with a type of adenomatous polyposis affecting the colon and duodenum, known as *MUTYH*-associated polyposis (MAP).³ This condition follows an autosomal recessive hereditary pattern (OMIM: 608456) and is linked to an elevated susceptibility to colorectal cancer^{2,3}; while there is speculation about an increased risk of other cancers beyond the digestive system, such as ovarian, endometrial and breast cancers, the pathogenic connection remains unclear.^{4,5}

Villy et al. described a case of medulloblastoma (MB) in a patient with MAP.⁶ The patient affected by MB molecular subgroup WNT carried the homozygous pathogenic variant c.1227_1228dup, p.(Glu410Glyfs*43) in *MUTYH*.⁶ They concluded that MB could be an

uncommon presentation of a biallelic germline pathogenic variant in *MUTYH*.⁶

Germline-predisposing pathogenic variants are detected in approximately 5% to 6% of individuals with MB and up to 20% in the SHH subgroup.⁷ Although a definitive consensus list is yet to be established, prominent predisposition genes have been identified, predominantly including *Adenomatous polyposis coli (APC)*, a regulator of the WNT signalling pathway; G Protein-Coupled Receptor 161 (*GPR161*); *Patched 1 (PTCH1)* and *suppressor of fused homologue (SUFU)*, both negative regulators of the Hedgehog signalling pathway; *Elongator Acetyltransferase Complex Subunit 1 (ELP1)*; and *Tumour Protein P53 (TP53)*.⁶⁻⁸ In this report, we describe a second and unrelated case of MB with compound heterozygous variants in the *MUTYH* gene.

The patient is a 2-year-old girl who was diagnosed at 18 months with an MB with extensive nodularity, which was SHH-activated and

This is an open access article under the terms of the [Creative Commons Attribution-NonCommercial-NoDerivs](https://creativecommons.org/licenses/by-nc-nd/4.0/) License, which permits use and distribution in any medium, provided the original work is properly cited, the use is non-commercial and no modifications or adaptations are made.

© 2024 The Authors. *Neuropathology and Applied Neurobiology* published by John Wiley & Sons Ltd on behalf of British Neuropathological Society.

TP53 wild type. Figures S1 and S2 show the brain MRI and histological features, respectively. The type of cancer detected suggested Gorlin syndrome, but the child did not exhibit any other features indicative of this condition. However, the family history indicated the occurrence of various gynaecological and a gastrointestinal neoplasm on the maternal side and a colonic neoplasm on the paternal side. The pedigree depicted in Figure 1 summarises the oncological family history. Genetic analysis was performed through next-generation sequencing (NGS) by using a custom clinical exome panel containing more than 8500 genes, including those involved in DNA cancer predisposition syndromes (Twist Bioscience, South San Francisco, CA, USA) on a NovaSeq 6000 platform (Illumina, San Diego, CA, USA).

After obtaining informed consent from the patient's parents for the germline genetic testing, pathogenic variants in *PTCH1/2*, *SUFU* and *ELP1* were excluded, and although less likely, pathogenic variants in *TP53* and *APC* were also ruled out. The genetic investigations identified c.1353_1355delCCT (p.Glu452del) and c.228G>T (p.Tyr76Ter) variants

in compound heterozygosity in the *MUTYH* gene (NM_001048173.1) (Figure 2). Both variants have been reported extensively in the literature in patients with polyposis or colon cancer.^{9–12} The indel variant, inherited from the mother and also found in the proband's brother, has an allele frequency of 0.00009544 in the general population (gnomAD) and can be classified as a pathogenic variant (Class 5) according to the American College of Medical Genetics (ACMG) guidelines¹³ (Table S1). The nonsense variant p.Tyr76Ter, inherited from the father, has an allele frequency of 0.0001096 in the general population (gnomAD) and can be classified as a pathogenic variant (Class 5) according to the ACMG guidelines. Genetic analysis was also performed on DNA extracted from the tumour tissue of the patient: the analysis confirmed the germline *MUTYH* (c.1353_1355del—AF: 0.54; c.228C>A—AF: 0.42) variants in heterozygosity and detected two somatic pathogenic variants in the *SMO* (c.1604G>T, p.Trp535Leu—AF 0.48), *KMT2D* (c.8906C>A, p.Ser2969Ter—AF: 0.49) and *TSC2* (c.275A>T; p.—Glu92Val—AF: 0.49) genes.

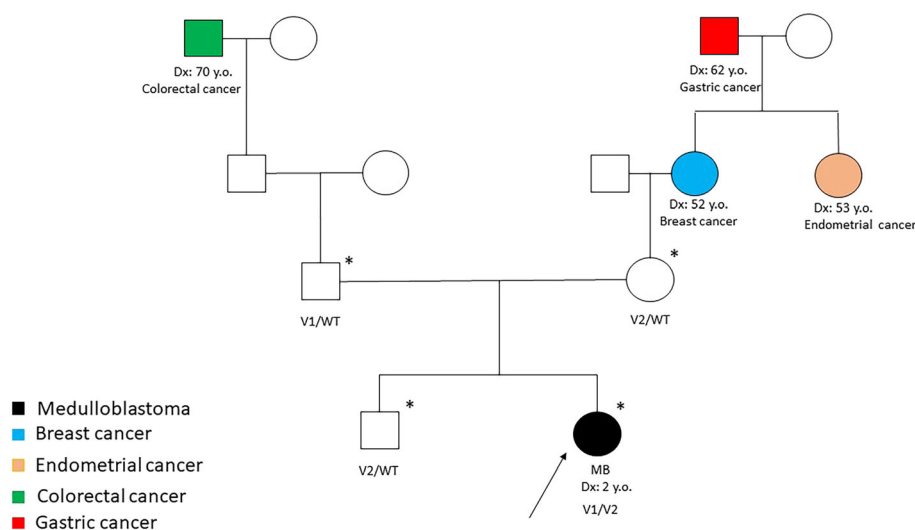


FIGURE 1 Pedigree of the family. An asterisk indicates the individuals who received DNA sequencing. Detection of the c.228G>T (V1) and/or c.1353_1355delCCT (V2) in *MUTYH* by genetic tests is indicated by the plus sign.

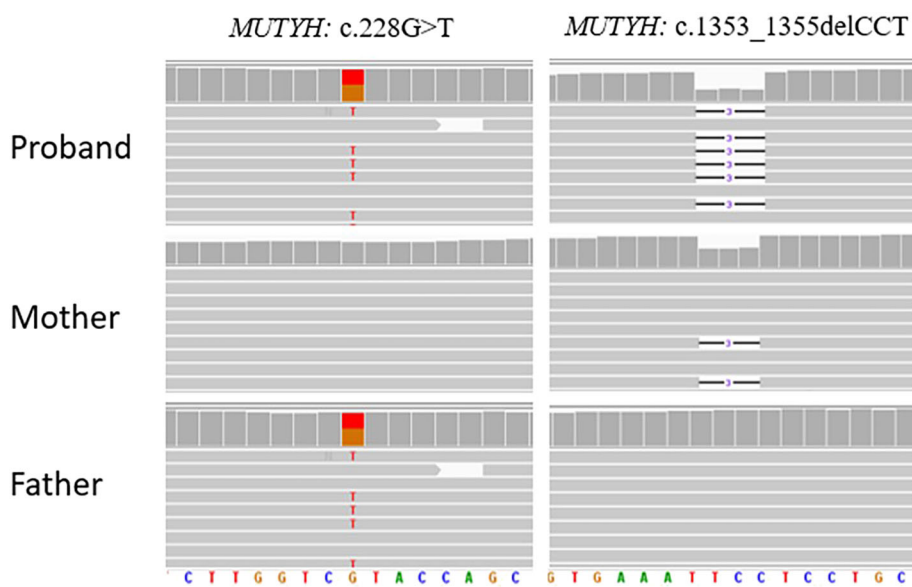


FIGURE 2 Each pane is an IGV screenshot of exome sequencing alignments for the proband (top track), mother (middle track) and father (bottom track). The variant c.228G>T in the *MUTYH* gene is shown on the left of the image (found in proband and proband's father), while the variant c.1353_1355delCCT in *MUTYH* gene is shown on the right of the image (found in proband and proband's mother).

Our case is the second case of *MUTYH*-associated MB reported in the literature.⁶ Villy et al. described a case of MB molecular subgroup WNT, which carried a homozygous pathogenic variant in the *MUTYH* gene and suggested that the MB could be an uncommon presentation of a biallelic germline pathogenic variant in *MUTYH*.⁶ In addition, Kline et al. described two paediatric patients with high-grade gliomas associated with an inactivating *MUTYH* germline pathogenic variant.¹⁴ Patient #2, described in the report, had a previous diagnosis of MB and showed a heterozygous germline loss-of-function variant of *MUTYH* and a second hit that deleted the wild-type allele of *MUTYH* in the tumour DNA; thus, MB is associated with *MUTYH* but is not related to tumour predisposition due to biallelic germline variants of *MUTYH* and *MAP/FAP2*.¹⁴

MAP/FAP2 is a recessive condition, but Win et al. reported that *MUTYH* heterozygotes have a mildly increased risk of gastric, hepatobiliary, endometrial and breast cancer.⁵ In addition, Patient #2 reported by Kline et al.,¹⁴ who carried a monoallelic *MUTYH* germline variant, and the family history of our case, which includes gastrointestinal and gynaecological neoplasms in the generation of the grandparents and great-grandparents who may be carriers of a heterozygous *MUTYH* germline variant, both suggest that monoallelic *MUTYH* variants may also confer slightly increased tumour risk with reduced penetrance.

When MB coexists with a family history of colon polyposis or colorectal cancer, it is imperative to investigate the role of *MUTYH*, as it may significantly predispose individuals to this rare form of cancer. Further research is needed to fully understand the genetic and molecular mechanisms underlying this association, but this case highlights the importance of considering *MUTYH* in the context of MB and related conditions. Understanding the role of *MUTYH* in MB cases with a family history of colorectal disease can provide valuable insights into the genetic factors contributing to this cancer. This knowledge can lead to improved screening and prevention strategies for affected individuals and their families.

The discovery of an MB case associated with a compound heterozygous mutation in *MUTYH* raises important questions about the potential connections between *MUTYH* and various cancer types.

Vogt et al. and Win et al. estimated that individuals with biallelic pathogenic variants in the *MUTYH* gene have an increased risk of urinary bladder and ovarian cancer, compared with the general population.^{5,15} Biallelic *MUTYH* pathogenic variants and extracolonic disease may include sebaceous carcinoma among the extracolonic manifestations, in addition to endometrial cancer, as seen in some colorectal cancer predisposition syndromes.⁵

This finding underscores the complexity of cancer genetics and the need for comprehensive genetic testing in cancer patients, especially those with a family history of colorectal lesions. It also emphasises the importance of collaboration between oncologists, genetic counsellors and researchers to better understand and address the genetic factors involved in cancer development.

Furthermore, this case highlights the role of advanced genetic sequencing techniques, such as NGS, in identifying rare genetic mutations that may contribute to cancer susceptibility. NGS allows for the

simultaneous analysis of multiple genes, enabling a more comprehensive assessment of a patient's genetic profile. As our understanding of cancer genetics continues to evolve, NGS and other advanced molecular techniques will play a crucial role in identifying individuals at increased risk and tailoring personalised treatment and prevention strategies.

In addition to its potential implications for MB research, this case also has broader implications for cancer genetics. The discovery of biallelic *MUTYH* pathogenic variants in an MB patient highlights the need to consider a wide range of genetic factors when assessing cancer risk. It underscores the importance of expanding genetic testing beyond well-established cancer predisposition genes and exploring less common, but significant genetic contributors to cancer susceptibility.

The frequency of *MUTYH* variants in the general population is approximately 1% to 2% and the association between *MUTYH* pathogenic variants and an increased risk of colorectal cancer has been well documented in the literature. The identification of biallelic *MUTYH* pathogenic variants in our MB patient, the second reported in the literature, strengthens the hypothesis that this tumour could be a rare association with tumour development, so the connection between *MUTYH* and MB is a relatively new and emerging area of research and needs further investigation as there may be perhaps other factors related to development as well. Furthermore, the monoallelic pathogenic variants in *MUTYH* could confer an increased risk of cancer with reduced penetrance.

ACKNOWLEDGEMENTS

The authors thank European Reference Network Genetic Tumour Risk Syndromes (ERN GENTURIS), Megan Eckley for helping in the English final version and the 'Il Laboratorio di Chiara' Foundation for their support. Open access funding provided by BIBLIOSAN.

PEER REVIEW

The peer review history for this article is available at <https://www.webofscience.com/api/gateway/wos/peer-review/10.1111/nan.12968>.

DATA AVAILABILITY STATEMENT

The data that support the findings of this study are available in the Supporting Information of this article.

PATIENT INFORMED CONSENT

Written informed consent for genetic analysis and data publication was obtained from both parents of the patient.

ORCID

Sabrina Rossi  <https://orcid.org/0000-0002-1477-8855>

REFERENCES

1. Kairupan C, Scott RJ. Base excision repair and the role of *MUTYH*. *Hered Cancer Clin Pract*. 2007;5(4):199-209. doi:10.1186/1897-4287-5-4-199

2. Al-Tassan N, Chmiel NH, Maynard J, et al. Inherited variants of MYH associated with somatic G:C→T:A mutations in colorectal tumors. *Nat Genet.* 2002;30(2):227-232. doi:[10.1038/ng828](https://doi.org/10.1038/ng828)
3. Colas C, Bonadona V, Baert-Desurmont S, et al. MUTYH-associated polyposis: review and update of the French recommendations established in 2012 under the auspices of the National Cancer institute (INCa). *Eur J Med Genet.* 2020;63(12):104078. doi:[10.1016/j.ejmg.2020.104078](https://doi.org/10.1016/j.ejmg.2020.104078)
4. Villy MC, Masliah-Planchon J, Buecher B, et al. Endometrial cancer may be part of the MUTYH-associated polyposis cancer spectrum. *Eur J Med Genet.* 2022;65(1):104385. doi:[10.1016/j.ejmg.2021.104385](https://doi.org/10.1016/j.ejmg.2021.104385)
5. Win AK, Reece JC, Dowty JG, et al. Risk of extracolonic cancers for people with biallelic and monoallelic mutations in *MUTYH*. *Int J Cancer.* 2016;139(7):1557-1563. doi:[10.1002/ijc.30197](https://doi.org/10.1002/ijc.30197)
6. Villy M, Warcoin M, Filser M, et al. First report of medulloblastoma in a patient with *MUTYH* -associated polyposis. *Neuropathology Appl Neurobio.* 2023;49(4):e12929. doi:[10.1111/nan.12929](https://doi.org/10.1111/nan.12929)
7. Waszak SM, Northcott PA, Buchhalter I, et al. Spectrum and prevalence of genetic predisposition in medulloblastoma: a retrospective genetic study and prospective validation in a clinical trial cohort. *Lancet Oncol.* 2018;19(6):785-798. doi:[10.1016/S1470-2045\(18\)30242-0](https://doi.org/10.1016/S1470-2045(18)30242-0)
8. Begemann M, Waszak SM, Robinson GW, et al. Germline *GPR161* mutations predispose to pediatric medulloblastoma. *JCO.* 2020;38(1):43-50. doi:[10.1200/JCO.19.00577](https://doi.org/10.1200/JCO.19.00577)
9. Halford SER, Rowan AJ, Lipton L, et al. Germline mutations but not somatic changes at the MYH locus contribute to the pathogenesis of unselected colorectal cancers. *Am J Pathol.* 2003;162(5):1545-1548. doi:[10.1016/S0002-9440\(10\)64288-5](https://doi.org/10.1016/S0002-9440(10)64288-5)
10. Gismondi V, Meta M, Bonelli L, et al. Prevalence of the Y165C, G382D and 1395delGGA germline mutations of the MYH gene in Italian patients with adenomatous polyposis coli and colorectal adenomas. *Int J Cancer.* 2004;109(5):680-684. doi:[10.1002/ijc.20054](https://doi.org/10.1002/ijc.20054)
11. Jones S. Biallelic germline mutations in MYH predispose to multiple colorectal adenoma and somatic G:C→T:A mutations. *Hum Mol Genet.* 2002;11(23):2961-2967. doi:[10.1093/hmg/11.23.2961](https://doi.org/10.1093/hmg/11.23.2961)
12. Ali M, Kim H, Cleary S, Cupples C, Gallinger S, Bristow R. Characterization of mutant MUTYH proteins associated with familial colorectal cancer. *Gastroenterology.* 2008;135(2):499-507.e1. doi:[10.1053/j.gastro.2008.04.035](https://doi.org/10.1053/j.gastro.2008.04.035)
13. Richards S, Aziz N, Bale S, et al. Standards and guidelines for the interpretation of sequence variants: a joint consensus recommendation of the American College of Medical Genetics and Genomics and the Association for Molecular Pathology. *Genet Med.* 2015;17(5):405-424. doi:[10.1038/gim.2015.30](https://doi.org/10.1038/gim.2015.30)
14. Kline CN, Joseph NM, Grenert JP, et al. Inactivating *MUTYH* germline mutations in pediatric patients with high-grade midline gliomas. *Neuro Oncol.* 2016;18(5):752-753. doi:[10.1093/neuonc/nov013](https://doi.org/10.1093/neuonc/nov013)
15. Vogt S, Jones N, Christian D, et al. Expanded extracolonic tumor spectrum in *MUTYH*-associated polyposis. *Gastroenterology.* 2009;137(6):1976-1985.e10. doi:[10.1053/j.gastro.2009.08.052](https://doi.org/10.1053/j.gastro.2009.08.052)

SUPPORTING INFORMATION

Additional supporting information can be found online in the Supporting Information section at the end of this article.

How to cite this article: Cipri S, Del Baldo G, Carai A, et al. A second case report of medulloblastoma in a patient carrying biallelic pathogenic *MUTYH* germline variants. *Neuropathol Appl Neurobiol.* 2024;50(2):e12968. doi:[10.1111/nan.12968](https://doi.org/10.1111/nan.12968)